

# Diaphragmatic hernia involving gravid uterus in a dog

Michela Ciccarelli,<sup>a,b</sup> Tania Perez,<sup>a</sup> William Dernell<sup>a</sup>

<sup>a</sup>Department of Veterinary Clinical Science, College of Veterinary Medicine, Washington State University, Pullman, WA;

<sup>b</sup>School of Molecular Bioscience, College of Veterinary Medicine, Washington State University, Pullman, WA

## Abstract

A 4-year German Shorthair Pointer pregnant dog was presented for severe tachypnea and depression. She had 1 natural breeding 52 days ago. Diaphragmatic hernia with intrathoracic displacement of the uterus was diagnosed via radiography and ultrasonography. Emergency herniorrhaphy was elected, and the owner requested to save the litter if possible. Right uterine horn tip, spleen, part of liver, pancreas, and part of greater omentum were in the thorax. Intraoperative transuterine ultrasonography confirmed live fetuses, and pregnancy was permitted to continue. Patient received supportive medical care for 3 days. Based on ultrasonography findings (eminent danger to litter), a decision was made to perform an emergency cesarean surgery (56 days after breeding). Six of 11 pups were alive, and 1 mummified fetus had an elongated neck (perhaps due to entrapment in the diaphragmatic hernia).

**Keywords:** Dog, pregnancy, herniorrhaphy, cesarean surgery, ultrasonography

## Background

Diaphragmatic hernia is the passage of abdominal organs into thoracic space through a diaphragmatic defect. It can occur as a congenital defect or secondary to trauma.<sup>1</sup> Traumatic diaphragmatic hernias are most commonly caused by car accidents (62–81%)<sup>2</sup>; less common causes are bite wounds and falls from a height. Traumatic muscular rupture or avulsion of diaphragm permits abdominal contents to enter the pleural cavity, resulting in reduced lung volume and subsequent dyspnea.<sup>3</sup> Liver is the most common organ to herniate (82–88%),<sup>4,5</sup> and its pressure on lungs further compromises lung expansion, leading to atelectasis and pleural effusion.<sup>3</sup> Entrapped intestines or stomach may become gas distended, obstructed, or ischemic, resulting in metabolic disturbances, decreased cardiac return, and sepsis.<sup>1</sup> Animals with acute traumatic diaphragmatic hernias may be presented in severe respiratory distress and shock and may require emergency surgery. Concurrent traumatic lesions are present in 25–38% of the cases.<sup>6</sup> In chronic diaphragmatic hernias, clinical signs may be nonspecific (e.g. vomiting or weight loss), requiring a complete evaluation to reach a definitive diagnosis.<sup>5</sup> Abdominal radiographs often provide a ready diagnosis of herniation, especially in an emergency setting. Animals with a traumatic

diaphragmatic hernia may have an indistinct diaphragmatic line, pleural effusion, dorsal displacement of lungs, and abnormal soft tissue opacities within the pleural space.<sup>7</sup> Right side hernias were reported to be more common (68%) and usually characterized by more than 1 organ herniated in the pleural space.<sup>7</sup> Erect dorsoventral radiographic images may improve the shift of the organ and visualization.

If the gastrointestinal tract is displaced in the chest, gastrointestinal contrast study may be helpful to confirm the diagnosis.<sup>8</sup> Whole-body computed tomography, although costly, has the ability to diagnose herniation and possible concurrent orthopedic, neurologic, and intra-abdominal injuries.<sup>9</sup> As an alternative to computed tomography, transabdominal ultrasonography may aid the diagnosis. Abdominal organs may be visualized in the thoracic cavity close to heart.<sup>8</sup>

Surgical repair is often the chosen treatment; however, it must be delayed until the patient is stable. High mortality rate (33%) was reported when the herniorrhaphy was performed within 24 hours after presentation.<sup>1</sup> Animals with chronic traumatic hernias are often referred to experienced surgeons for treatment, particularly when the liver is involved, because

\*Presented (abstract) at the Society for Theriogenology 2022 conference; authors acknowledge that right uterine horn was herniated (not left uterine horn as published in the conference proceedings), and error is regretted.

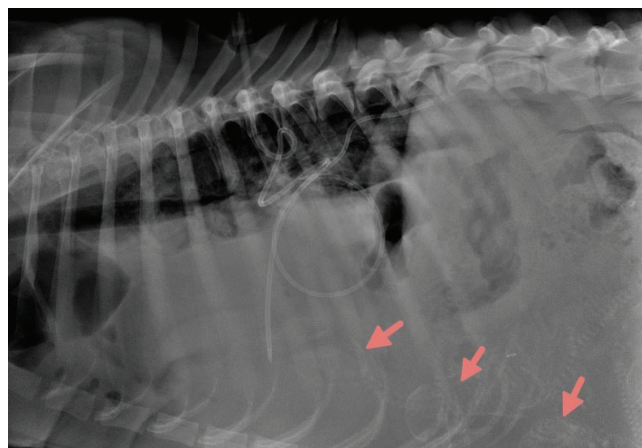
of extensive adhesions. In some of these patients, a prosthetic implant, transversus abdominal muscle flap, or diaphragmatic advancement may be required to close the hernia.<sup>5</sup> To our knowledge, apparently, no previous reports documented herniation of pregnant uterus into thoracic space, pregnancy continuation, and delivery of viable pups after herniorrhaphy.

## Case presentation

A 4-year 34 kg pregnant female German Shorthair Pointer was referred for severe respiratory distress that started 2 days before presentation. She had 1 natural breeding 52 days ago. Owner reported trauma of unknown origin a year previously that led to pleural effusion and respiratory distress that were treated medically.

At presentation, the patient was quiet and alert and had hyperemic mucous membranes. Abdomen felt soft and nonpainful, and fetuses were palpable in the caudal abdomen. Her heart rate was 100 beats/minute, and normal sinus arrhythmia was noted. There was no enlargement of her peripheral lymph nodes, and her rectal temperature was 38°C. There were muffled lung sounds of the ventral lung lobes on auscultation. She was ~5% dehydrated. Radiographs revealed substantial amount of soft tissue presence in the pleural space. Right lung lobes appeared dorsally displaced, and an abnormally mineralized fetus was superimposed over the caudal thorax. Several other normal fetuses were in the cranial abdomen (Figure 1). All above findings confirmed a suspected diaphragmatic hernia involving pregnant uterus. Intravenous lactated Ringer's solution (Vetivex® [veterinary pHyLyte injection 7.4; balanced electrolyte solution] 140 ml/kg/24 hours) was given for hypovolemia. Oral tramadol (2 mg/kg), intravenous acepromazine (0.02 mg/kg), and intravenous butorphanol (0.4 mg/kg) were given for pain control and tranquilization.

It was estimated that the patient had at least 1 week to whelp. This was based on breeding history (1 breeding based on 1 progesterone concentrations [5.6 ng/ml] determination), calculation of biparietal diameter (based on average [24 mm] of 2 pups), and a lack of fetal intestinal peristalsis evaluated via ultrasonography. Due to the large litter size (11–12 pups,



**Figure 1.** Lateral thoracic radiograph. Note displaced lung lobes and mineralized fetal skeletons (arrows) in thorax.

determined via radiographs) and fetal rapid growth during the final weeks of pregnancy, increased compression on the lungs and additional patient compromise was predicted.

## Treatment

Surgery for hernia repair was deemed necessary. Blood was drawn to evaluate progesterone concentrations before herniorrhaphy to aid in deciding on whether to maintain pregnancy. Progesterone concentrations were 6.37 ng/ml, which is sufficient to maintain pregnancy.<sup>10</sup> After discussing options, owner elected herniorrhaphy and pregnancy maintenance. Preoperative blood work revealed the following: anemia (packed cell volume 30% [reference range {RR}: 36–56%]), hypocalcemia (8.4 mg/dl [RR: 9–11.3 mg/dl]), hyponatremia (147 meq/l [RR: 149–158 meq/l]), hypochloremia (110 meq/l [RR: 112–119 meq/l]), slightly lower creatinine (0.6 mg/dl [RR: 0.8–1.6 mg/dl]), albumin (2.1 g/dl [RR: 2.9–3.8 g/dl]), and total proteins (5.1 g/dl [RR: 5.5–7.5 g/dl]). Chest tubes were placed bilaterally for aspiration of thoracic fluid. Preoperative medications included intravenous methadone (0.5 mg/kg) and cefazolin (22 mg/kg). General anesthesia was induced with intravenous propofol (0.88 mg/kg) and maintained with sevoflurane in 100% oxygen. Patient was kept on mechanical ventilation (5 breaths/minute). A ventral midline celiotomy was performed. Left uterine horn was exteriorized, a 7 cm tear was noted on the right side extending from the tendinous portion of the diaphragm into the pars sternalis. Thoracic cavity had right uterine horn tip, spleen, right medial, and lateral lobes of liver, pancreas, adjacent small intestine, and part of omentum. Herniorrhaphy was performed using Lambert and simple continuous patterns. A rotational flap of the internal oblique muscle aided in the closure of the most ventral portion of the hernia. Porcine submucosa was sutured over the herniorrhaphy for additional reinforcement. Bronchodilators, inhalation albuterol (1 puff [90 µg]), and intravenous terbutaline (0.005 mg/kg) were given to improve oxygenation. Before closure, intraoperative transuterine ultrasonography was performed. Four fetuses were visualized; fetal heart rates ranged from 60 to 70 beats/minute that indicated fetal stress (attributed to uterine circulation compromise and anesthesia). Routine closure of the linea alba was performed. Postoperative analgesia included a continuous rate infusion of intravenous fentanyl (3 µg/kg/1 hour) and intravenous methadone (0.25 mg/kg) as needed. Intravenous lactated Ringers (Vetivex® [140 ml/kg/2 hours]) and 6% hydroxyethyl starch 130/0.4 in 0.9% sodium chloride (VetStarch™ Zoetis [31 ml/kg]) for 1 hour were given to maintain normal volemia. Antibiotic therapy consisted of intravenous ampicillin (22 mg/kg, once every 6 hours) and amoxicillin-clavulanic acid (20 mg/kg, once every 12 hours). A day after surgery, 1 ml (0.088 mg/kg) of oral altrenogest was empirically given to aid in maintaining uterine quiescence and prevent premature delivery. Thoracic fluid was continuously drained. Temperature, heart rate, respiratory rate, packed cell volume, total proteins, blood glucose, blood urea nitrogen, lactate, and fetal well-being were monitored every 2 hours. Fetal heart rates returned to normal, which ranged from 204 and 260 beats/minute 2 hours after recovery. However, 36 hours after surgery, 3 fetuses had no heartbeat, and 3 others had heart rates between 204 and 275 beats/minute. Blood chemistry and Complete Blood Count (CBC) revealed hypoalbuminemia (2.1 g/dl [RR: 2.9–3.8 g/dl]), leukocytosis ( $28.1 \times 10^3/\mu\text{l}$  [RR:  $4.5\text{--}16 \times 10^3/\mu\text{l}$ ]) with a left shift neutrophilia (segmented neutrophils  $22.480 \times 10^3/\mu\text{l}$  [RR:  $2.8\text{--}13.4 \times 10^3/\mu\text{l}$ ]), and elevated liver enzymes (alanine aminotransferase 878 U/L [RR: 0–100 U/L] and alkaline phosphatase 107 U/L [RR: 0–96 U/L]). Due to inflammatory

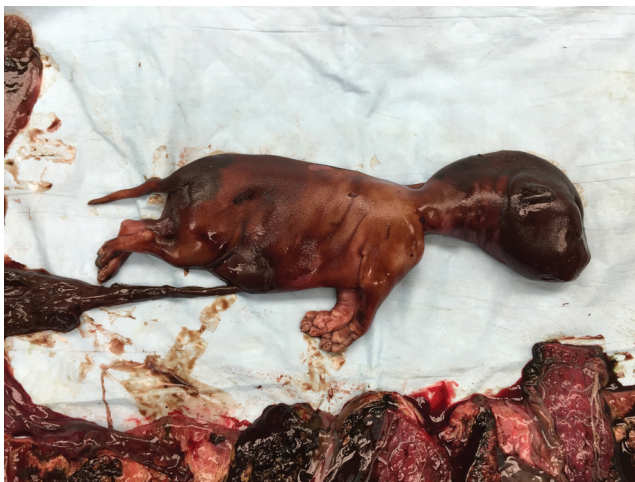leukogram associated probably with dead fetuses and previous herniorrhaphy, an emergency cesarian surgery was elected. Due to urgency to have the procedure and to avoid fetal depression, premedication was avoided, and general anesthesia was induced with intravenous propofol (4 mg/kg) and maintained with sevoflurane in 100% oxygen. Celiotomy through the previous incision was performed. Uterus was exteriorized, fetuses were delivered, and ovariohysterectomy was performed. Six pups were resuscitated with mild effort and immediately placed in a pup incubator with controlled temperature (29.4–32.2 °C), oxygen (40–60%), and humidity (55–65%). Plasma (1.5 ml/100 g body weight) typed for the patient was given subcutaneously to prevent passive transfer failure. Pups were fed by an orogastric tube using a milk replacer (1–2 µl/100 g body weight). Average body weight was 70 g. Patient was given intravenous methadone (0.25 mg/kg) for pain control and intravenous cefazolin (22 mg/kg). Patient also received intravenous lactated Ringers (Vetivex® [140 ml/kg/24 hours]) and intravenous VetStarch™ (31 µl/kg/1 hour). A blood transfusion (150 ml whole blood) was given to restore packed cell volume and total protein concentrations. Patient recovered uneventfully from the second surgery; however, she was not producing milk. Over the 24 hours after cesarean surgery, an increase in the mammary gland development and milk production was observed, so she was weaned off intravenous medications and reunited with her pups.

## Outcome

Six of 11 pups were successfully resuscitated; 2 were severely autolyzed, and 1 was mummified with neck incarceration in the hernia (Figure 2). Other 3 nonviable pups were in good postmortem condition, consistent with recent death. Apgar score of pups delivered alive was 4–5. Patient remained stable and began to eat the day after cesarean surgery, and she was discharged from the hospital 48 hours later. Dog and pups were doing well at examination on day 15.

## Discussion

Diaphragmatic hernia in dogs is usually caused by trauma and may be life-threatening if not diagnosed immediately. However, in this case, there are situations in which less severe



**Figure 2.** Mummified fetus. Note the elongation of neck and incarceration.

herniation becomes chronic and remains undiagnosed.<sup>5</sup> It was speculated that incarceration of 1 of the growing fetuses in the diaphragmatic lesion occluded the defect, allowing initially normal respiration. However, with pregnancy advancement, additional pressure from the enlarging uterus forced more abdominal organs into the thoracic cavity, jeopardizing the lives of dog and pups.

Pregnancy complicated anesthesia induction, maintenance, and monitoring. However, for both surgeries performed in this patient, the anesthetic protocol was chosen carefully considering the anesthetized patient's stability and the survival of the near-term fetuses. General anesthesia in pregnant dogs is best induced with injectable anesthetics that allow smooth induction and rapid intubation. In this report, the patient was induced with propofol because of its rapid onset and minimal residual effect on pups.<sup>11–13</sup> Although propofol crosses the placenta and is eliminated slower by pups than dog, it stimulated lesser neurologic depression than pups delivered from dogs induced with ketamine and midazolam.<sup>14</sup> Compared to other drugs, propofol had no negative effect on pup breathing, movement, or vocalization after delivery via cesarean surgery.<sup>15</sup> In this case, sevoflurane was used to maintain anesthesia because it has a very rapid induction and recovery, and it is rapidly eliminated by the neonate. Isoflurane can be used if sevoflurane is not available since it has been associated with better neonatal survival at 7 days compared to methoxyflurane, xylazine, and ketamine.<sup>16</sup> However, it may have dose-dependent side-effects like vasodilation, resulting in hypotension and respiratory depression. In general, inhaled anesthetics has been associated with decreased breathing in pups after cesarean surgery.<sup>15</sup> Local epidural would have been helpful in this case to decrease the amount of anesthetics necessary and reduce fetal absorption. It has been demonstrated that epidural anesthesia produced the least neurologic and respiratory depression in neonates after cesarean surgeries compared to injectable or inhaled anesthetics.<sup>14</sup> To reduce pain associated with surgery, opioids are frequently used because they minimally affect cardiac output, systemic blood pressure, and oxygen delivery. However, they can induce bradycardia in pups after delivery requiring an opioid antagonist (e.g. naloxone) treatment.<sup>17</sup> As the patient was experiencing moderate pain in the present report, methadone was given after pups delivery. Most common complication after diaphragmatic hernias repair is pneumothorax, and the recurrence of pulmonary edema was preemptively avoided with bronchodilators treatment.

In dogs, the extremely variable estrous cycle length and the prolonged time that sperm can remain viable in the female reproductive tract lead to whelping from 57 to 72 days after breeding.<sup>18</sup> Serum progesterone concentrations measured during proestrus to determine Luteinizing Hormone (LH) surge allow for the most accurate estimate of the whelping day. Parturition is expected  $65 \pm 2$  days after LH surge.<sup>19,20</sup> Stillbirth and perinatal death are common in preterm delivery; in fact, just before parturition, the physiologic increases in cortisol concentrations are fundamental for final pulmonary maturation. Thus, premature pups present with respiratory distress due to lung structure immaturity and lack of pulmonary surfactant leading to hypoxia and death.

The highest mortality rate is if they are delivered  $\geq 5$  days before the due date.<sup>21</sup> In this case, the only information available from the history was the breeding date, and

determination of 1 progesterone concentrations (5.6 ng/ml) on day 2 before breeding made it impossible to determine the exact due date. Pregnancy length was determined via radiography and ultrasonography. Radiographs have mineralization of some fetal structures that can help determine a range of pregnancy length. However, the fetuses may be completely mineralized as early as 58 days after LH surge, at which time, they would not survive extrauterine life.<sup>19,22</sup> Ultrasonography is considered a better tool to assess pregnancy length and fetal maturity. In late pregnancy, measurement of biparietal diameter of fetuses is considered accurate, together with assessment of body diameter.<sup>23,24</sup> In the present case, biparietal diameter of the fetuses was, on average 24 mm, suggested that the patient was 8 days from parturition.<sup>25</sup> Ultrasonography is also used to evaluate organ development and estimate pregnancy length. Best organs to evaluate pregnancy end are fetal gastrointestinal tracts and kidneys. Intestines will start having peristalsis at 62–64 days of pregnancy that persisted near term.<sup>25</sup> Kidneys have a clear differentiation of the cortex and medulla closer to term.<sup>26</sup> In the present case, repeated ultrasonographic evaluations were performed, primarily to appreciate fetal stress and the presence or absence of heartbeat. More attention should have been given to fetal organ development to better estimate pregnancy length. The presence of live fetuses observed intraoperatively during the herniorrhaphy procedure allowed us to decide whether pregnancy can be maintained.

Normal heart rate of a canine fetus is between 220 and 240 beats/minute.<sup>27</sup> Heart rates < 140–160 beats/minute indicate stress due to hypoxia. In the present case, the fetal heart rates were lower during the hernia repair; however, they returned to normal immediately after surgery. Ultrasonographic evaluation 2 days after surgery identified the presence of dead fetuses that led to the emergency cesarean surgery.

An important consideration of this case is the risk taken in performing the hernia repair while maintaining pregnancy. Pregnant animals are at a higher risk of death and abortion when undergoing surgery. This is due to many physiologic changes that pregnancy induces in the body, including increased plasma volume with a resulting decrease in packed cell volume and total proteins, leading to decreased oncotic pressure, decreased protein binding drugs, and increased cardiac output. Increased abdominal pressure leads to decreased venous return and less uterine perfusion. Change in gastrointestinal tract pH leads to vomiting, reflux, and aspiration under anesthesia. Another factor exacerbating abdominal surgery risk is the dorsal recumbency of the patient that induces vena cava compression with an additional decrease in venous return, maternal hypotension, and decreased perfusion of the placenta. In the present case, the patient was already severely compromised due to diaphragmatic hernia. Therefore, some pups may have died during the hernia repair for reasons discussed above. Additionally, pregnant uterus was manipulated and kept outside the abdomen for some time during herniorrhaphy that could have caused uterine contractions (reason for giving altrenogest to the patient after surgery).

Apparently, there are only a few case reports describing diaphragmatic herniation of pregnant uterus in dogs, and they reported either negative or unknown outcomes.<sup>28</sup> First report described a 2-year Maltese dog with dyspnea and cyanosis that had 1 gravid horn herniating into thoracic cavity. Dog made a complete recovery after diaphragmatic hernia repair;

however, there was no information regarding fetal outcome.<sup>29</sup> A second case described a 17-month Afghan dog, bred 59 days before presentation, that was a victim of an accident that led to episodes of acute respiratory distress. Lateral radiograph revealed fetal skeleton in the chest. One viable pup was delivered via cesarean surgery. Pup attempted to suckle after surgery; however, it was euthanized shortly thereafter due to a cleft palate, although the dog made a complete recovery.<sup>30</sup> Another report involved a 3-year intact female Pointer that was examined for anorexia, lethargy, and green vaginal discharge. Cranial abdominal and thoracic radiographs revealed a peritoneal-pericardial diaphragmatic herniation with 1 mineralized fetus in the pericardial sac. Dog died shortly after radiographs were taken, and the diagnosis was confirmed on postmortem examination.<sup>31</sup> A recent report<sup>32</sup> documented a mixed breed pregnant dog that was adopted and presented for a 10-day duration of breathing effort. Radiographs revealed that 4 pups were in the chest and 3 in the abdomen. Dog underwent an emergency herniorrhaphy and ovariohysterectomy and had 6 live pups.<sup>32</sup> The dog also had chronic diaphragmatic hernia with herniation of the gravid uterus.<sup>28</sup> Dog was hit by a car 1 year before and was presented for severe dyspnea. Pups were unwanted, so the dog underwent emergency herniorrhaphy and ovariohysterectomy.<sup>28</sup> Apparently, there are no reports of herniation of pregnant uterus into the thoracic space and pregnancy continuation, and delivery of healthy pups after herniorrhaphy.

## Learning points

- Day of ovulation is estimated by detecting LH surge; however, the determination of exact day of ovulation or day 1 of diestrus is the most accurate method to ascertain fetal readiness for birth.
- If day of ovulation was not determined, ultrasonographic fetal measurements and organ development coupled with radiographic findings may aid in estimating the whelping date and to time cesarean surgery to deliver viable pups.
- Anesthetized dog's stability and the well-being of near-term fetuses have to be considered in formulating anesthetic protocols.
- Intraoperative transuterine ultrasonography can be safely performed to assess fetal viability.

## Conflict of interest

Authors disclose no conflicts of interest.

## References

1. Boudrieau RJ, Muir WW: Pathophysiology of traumatic diaphragmatic hernia in dogs. *Compend Contin Educ Pract Vet* 1987;9:379–385, 386.
2. Gibson TWG, Brisson BA, Sears W: Perioperative survival rates after surgery for diaphragmatic hernia in dogs and cats: 92 cases (1990–2002). *J Am Vet Med Assoc* 2005;227:105–109. doi: 10.2460/javma.2005.227.105
3. Worth AJ, Machon RG: Traumatic diaphragmatic herniation: pathophysiology and management. *Compend Contin Educ Pract Vet* 2005;12:178–191.

4. Wilson GP, Newton CD, Burt JK: A review of 116 diaphragmatic hernias in dogs and cats. *J Am Vet Med Assoc* 1971;159:1142–1145.
5. Minihan AC, Berg J, Evans KL: Chronic diaphragmatic hernia in 34 dogs and 16 cats. *J Am Anim Hosp Assoc* 2004;40:51–63. doi: 10.2460/javma.2005.227.105
6. Schmiedt CW, Tobias KM, Stevenson MAM: Traumatic diaphragmatic hernia in cats: 34 cases (1991–2001). *J Am Vet Med Assoc* 2003;222:1237–1240. doi: 10.2460/javma.2003.222.1237
7. Hyun C: Radiographic diagnosis of diaphragmatic hernia: review of 60 cases in dogs and cats. *J Vet Sci* 2004;5:157–162. doi: 10.4142/jvs.2004.5.2.157
8. Williams J, Leveille R, Myer CW: Imaging modalities used to confirm diaphragmatic hernia in small animals. *Compend Contin Educ Pract Vet* 1998;20:1199–1210.
9. Hamilton T: Traumatic and incisional hernias. In: Aronson LR, editor. *Small animal surgical emergencies*. 2nd edition. Wiley Online Library; Hoboken, New Jersey, 2022. p. 190–198.
10. Verstegen-Onclin K, Verstegen J: Endocrinology of pregnancy in the dog: a review. *Theriogenology* 2008;70:291–299. doi: 10.1016/j.theriogenology.2008.04.038
11. Moore J, Bill KM, Flynn RJ, et al: A comparison between propofol and thiopentone as induction agents in obstetric anaesthesia. *Anaesthesia* 1989;44:753–757. doi: 10.1111/j.1365-2044.1989.tb09263.x
12. Sifaka I, Vadalouca A, Gatzidou B, et al: A comparative study of propofol and thiopental as induction agents for elective caesarean section. *Clin Exp Obstet Gynecol* 1992;19:93–96.
13. Valtonen M, Kanto J, Rosenberg P: Comparison of propofol and thiopentone for induction of anaesthesia for elective caesarean section. *Anaesthesia* 1989;44:758–762. doi: 10.1111/j.1365-2044.1989.tb09264.x
14. Luna SPL, Cassu RN, Castro GB, et al: Effects of four anaesthetic protocols on the neurological and cardiorespiratory variables of puppies born by caesarean section. *Vet Rec* 2004;154:387–389. doi: 10.1136/vr.154.13.387
15. Moon-Massat PE, Erb HN: Perioperative factors associated with puppy vigor after delivery by cesarean section. *J Am Anim Hosp Assoc* 2002;38:90–96. doi: 10.5326/0380090
16. Moon PE, Erb HN, Ludders JW, et al: Perioperative risk factors for puppies delivered by cesarean section in the United States and Canada. *J Am Anim Hosp Assoc* 2000;36:359–368. doi: 10.5326/15473317-36-4-359
17. Mathews KA, Dyson DH: Analgesia and chemical restraint for the emergent patient. *Vet Clin North Am Small Anim Pract* 2005;35:481–515. doi: 10.1016/j.cvsm.2004.10.012
18. Concannon P, Whaley S, Lein D, et al: Canine gestation length: variation related to time of mating and fertile life of sperm. *Am J Vet Res* 1983;44:1819–1821.
19. Rendano VT Jr., Lein DH, Concannon PW: Radiographic evaluation of prenatal Development in the Beagle. *Vet Radiol* 1984;25:132–141. doi: 10.1111/j.1740-8261.1984.tb01924.x
20. Shille VM, Gontarek J: The use of ultrasonography for pregnancy diagnosis in the bitch. *J Am Vet Med Assoc* 1985;187:1021–1025.
21. Kgm DC, Jo N. Towards scheduled pre-parturient caesarean sections in bitches. *Reprod Domest Anim Zuchthyg* 2020;55:38–48. doi: 10.1111/rda.13669
22. Toal RL, Walker MA, Henry GA: A comparison of real-time ultrasound, palpation and radiography in pregnancy detection and litter size determination in the bitch. *Vet Radiol* 1986;27:102–108. doi: 10.1111/j.1740-8261.1986.tb00013.x
23. Kutzler MA, Yeager AE, Mohammed HO, et al: Accuracy of canine parturition date prediction using fetal measurements obtained by ultrasonography. *Theriogenology* 2003;60:1309–1317. doi: 10.1016/S0093-691X(03)00146-8
24. Beccaglia M, Luvoni GC: Comparison of the accuracy of two ultrasonographic measurements in predicting the parturition date in the bitch. *J Small Anim Pract* 2006;47:670–673. doi: 10.1111/j.1748-5827.2006.00108.x
25. Lopate C: Estimation of gestational age and assessment of canine fetal maturation using radiology and ultrasonography: a review. *Theriogenology* 2008;70:397–402. doi: 10.1016/j.theriogenology.2008.05.034
26. Nyland TG, Mattoon JS: *Small animal diagnostic ultrasound*. Elsevier Health Sciences; New York, 2002.
27. Gil EMU, Garcia DAA, Giannico AT, et al: Canine fetal heart rate: do accelerations or decelerations predict the parturition day in bitches? *Theriogenology* 2014;82:933–941. doi: 10.1016/j.theriogenology.2014.04.025
28. Deschamps JY, Kolb H, Descol C, et al: Chronic diaphragmatic hernia with herniation of the gravid uterus in a female dog – a case report and a review. *Rev Med Veterinaire* 2012;163:299–301.
29. Sullivan JL, Puckett JR, Sevedge JP: Ruptured diaphragm with herniation of the gravid uterus and abdominal viscera. *J Am Vet Med Assoc* 1969;155:941–942.
30. Bellenger CR, Milstein M, McDonell W: Herniation of gravid uterus into the thorax of a dog. *Mod Vet Pract* 1975;56:553–555.
31. Iwasaki M, Serman FDA, Fonseca AC: What is your diagnosis? Peritoneopericardial diaphragmatic hernia with herniation of mineralized fetuses. *J Am Vet Med Assoc* 1999;214:1775–1776.
32. Merbl Y, Kelmer E, Shipov A, et al: Resolution of persistent pneumothorax by use of blood pleurodesis in a dog after surgical correction of a diaphragmatic hernia. *J Am Vet Med Assoc* 2010;237:299–303. doi: 10.2460/javma.237.3.299