

# Premature germ cells in the ejaculate of a 4-year-old male Labrador Retriever



James Barrett,<sup>a</sup> Jamie Douglas,<sup>b</sup> Christopher Premanandan,<sup>c</sup> Robyn Wilborn<sup>b</sup>

<sup>a</sup>Baytree Animal Hospital, Valdosta, GA

<sup>b</sup>Department of Clinical Sciences, College of Veterinary Medicine, Auburn University, Auburn, AL

<sup>c</sup>Department of Veterinary Biosciences, College of Veterinary Medicine, The Ohio State University, Columbus, OH

## Abstract

A healthy, 4-year-old, Labrador Retriever was presented for routine semen collection for cryopreservation. Ejaculate had an abundance of atypical round cells along with substantial morphologically abnormal sperm. Atypical round cells were identified as premature germ cells, indicating testicular insult or damage of unknown etiology. After multiple visits and a period (3 months) of rest from heavy training, premature germ cells were not observed and noticeable improvement in sperm morphology was evident. Apparently, changes observed were induced by heat stress given the location and intensity of training, season of the year, history and signalment of the patient, and the fact that all parameters improved following temperature management changes and rest from training. This case illustrated the importance of recognizing an unusual cell type during a routine semen analysis and to arrive at a possible etiology and resolution of the clinical problem.

**Keywords:** Canine, semen analysis, spermatogenesis, premature germ cells

## Case presentation

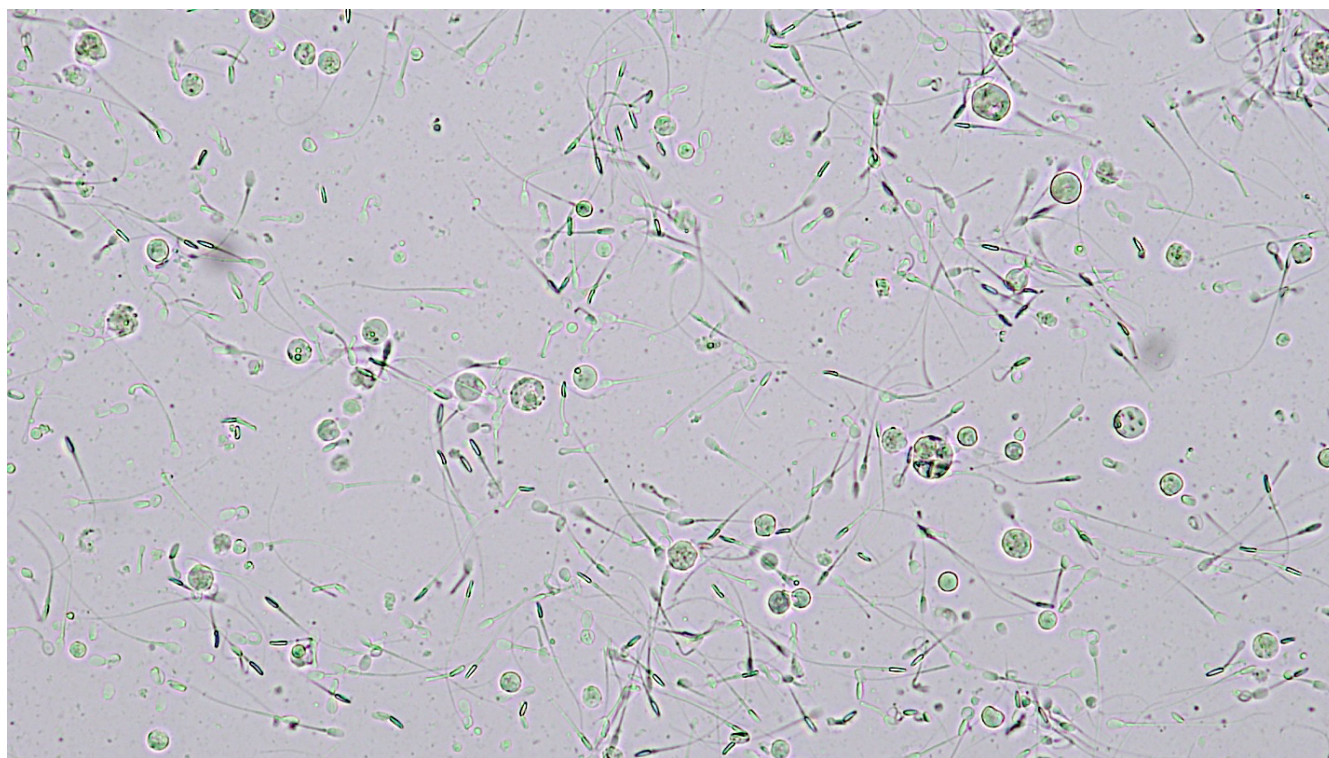
A 4-year-old, 30.6 kg (67.3 lb), black, intact male Labrador Retriever was presented to the Auburn University College of Veterinary Medicine Bailey Small Animal Teaching Hospital for semen collection and cryopreservation. The patient, a working field trial retriever, had returned from several months of heavy training 2 weeks before presentation. Semen had been collected 6 months earlier, and the spermogram had abnormal sperm morphology and low total sperm numbers. Additionally, during an earlier visit for semen collection, patient exhibited apprehension and had decreased libido.

Patient was bright, alert, and responsive. Vital signs were within normal limits. Penis, prepuce, testes, and scrotum had no obvious

abnormalities. Prostate was not digitally (transrectal) palpated in an effort to reduce negative influences on libido and semen collection. An ejaculate was collected using manual stimulation and teasing was accomplished using preserved vaginal scent swabs collected from an estrous female. Adequate libido was observed, and the patient readily ejaculated 2 ml (normal range: 1 - 30 ml<sup>1</sup>) of semen. Ejaculate was white and total sperm motility, determined via subjective analysis, was 60%, with 50% progressive motility. Concentration, quantified by a hemocytometer, was 67 x 10<sup>6</sup>/ml with a total sperm number (TSN) of 134 x 10<sup>6</sup>. Ideal TSN range is 300 x 10<sup>6</sup> - 2 x 10<sup>9</sup>, with at least 70% progressively motile and morphologically normal sperm.<sup>1,2</sup> Sperm morphology was examined using eosin-nigrosin stain and only 8% of sperm had normal shape/structure (Table 1). On wet-mount motility examination, multiple atypical round cells were identified (Figure 1).

**Table 1.** Sperm morphology evaluation on initial presentation for evaluation

Normal morphology	Abnormal heads	Abnormal midpieces	Tailless	Proximal droplets	Distal droplets	Bent tails	Coiled tails
8%	63%	32%	14%	2%	0%	0%	10%



**Figure 1.** Photomicrograph of wet-mount preparation admixed with sperm (200 x magnification). Note atypical round cells (premature round cells).

Atypical round cells identified on cytology are considered premature germ cells (PGCs) or sperm cell precursors. These cells are released prematurely from seminiferous tubules of spermatogenic epithelium and are commonly referred to as spheroids due to their characteristic round shape. Their presence in semen indicated aberrations in spermatogenesis.<sup>3</sup> Patient was discharged with instructions to return in 3 weeks for further diagnostic evaluation and semen analysis.

### Treatment

After ~ 3 weeks, the patient returned for evaluation and was bright, alert, and responsive. Physical examination findings were again unremarkable except for an elevated rectal temperature of 103.2°F (normal range 100.5 -102.5°F). Semen was collected as before. Libido was adequate and an ejaculate was easily collected. A low volume (0.5 ml) white ejaculate was obtained. Based on subjective analysis total and progressive sperm motility were 40 and 30%, respectively. Sperm concentration was  $30 \times 10^6/\text{ml}$  and TSN was  $15 \times 10^6$ . Morphological evaluation using eosin-nigrosin stain revealed that only 6% of sperm had normal shape/structure (Table 2). Similar round cells were again observed in the spermogram (Figure 2); however, rest of the cytology was unremarkable with no neutrophils or other evidence of inflammation. The round cells were interpreted to be PGCs based on their small size and higher nuclear to cytoplasmic ratio. Further diagnostic tests at this visit included the following: complete blood count and serum biochemistry profile, urinalysis, abdominal,

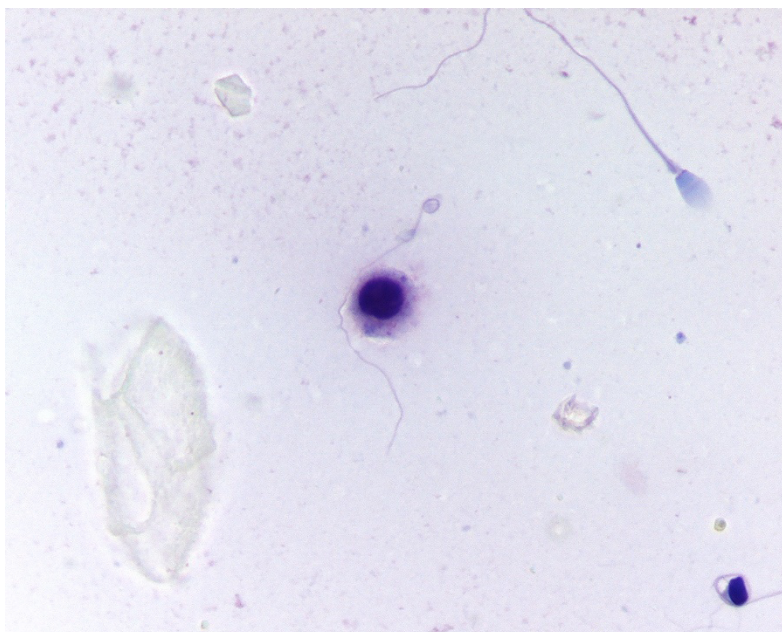
and testicular ultrasonography, and semen culture. Laboratory results were within normal limits. Abdominal and testicular ultrasonographic examinations were unremarkable. Semen culture had no bacterial growth. Earlier, the patient had tested (rapid slide agglutination test) negative for *Brucella canis*.

Results of diagnostic tests and lack of signs of systemic illness confirmed that the patient was in good overall health. Atypical round cells, decreased TSN, and abnormal sperm suggested that the patient had suffered a testicular damage or insult. Whereas this damage or insult had no apparent adverse impact on general health, it disrupted spermatogenesis and reduced fertility.

Theriogenologist overseeing the patient recommend rest from all training and vigorous exercise for 3 months, with monthly semen evaluations to determine whether resumption of normal spermatogenesis was possible. Return of normal spermatogenesis would be implied by improvement of sperm quality and disappearance of PGCs in ejaculate. By brief discontinuation of training, potential thermal or psychological stressors could be removed. Unfortunately, the patient was actively campaigning as a trialing retriever, and it was not feasible to stop work. Continuation of training activities associated with upcoming trials superseded the need to cryopreserve semen at that period. Once the current competition season ended, semen collection and reevaluation could be performed following a minimum rest period of at least 60 days.

**Table 2.** Sperm morphology evaluation on follow-up examination 3 weeks after initial visit

Normal morphology	Abnormal meads	Abnormal midpieces	Tailless	Proximal droplets	Distal droplets	Bent tails	Coiled tails
6%	46%	32%	14%	2%	4%	14%	22%

**Figure 2.** Photomicrograph of eosin-nigrosin stained preparation (200 x magnification). Note 1 deeply stained round cell (premature germ cell).

### Outcome

On initial semen evaluation following a designated rest period of 3 months, the patient's ejaculate was assessed again for possible cryopreservation. Two ejaculates were collected and assessed, and improvement in sperm quality was noted. First ejaculate had 60% total motility and 50% progressive motility, and the second ejaculate had 70% total motility and 60% progressive motility. Although PGCs were present, the number had substantially reduced, based on change in percentage (4 to 1% PGCs). Despite improved motility parameters, sperm morphology and concentration (TSN  $444 \times 10^6$ ; 41% normal morphology) were still less than ideal, and semen cryopreservation was not attempted. Patient's rest from training was extended by 1 more month. There was an improvement in normal sperm morphology and concentration (TSN  $978 \times 10^6$ ; 42% normal morphology). A bitch in estrus accompanied the patient at this appointment and served as the tease source for semen collection. Increased libido was observed for this collection and attributed to the presence of the female; thus future semen col-

lections for this patient were performed with a bitch in estrus. Patient returned after 1 week for semen collection. A total of 11 ml of ejaculate was collected. Total sperm motility was 80% and progressive sperm motility was 70%. Sperm concentration was  $80 \times 10^6/\text{ml}$  and TSN was  $880 \times 10^6$ . Although the semen had only 42% morphologically normal sperm (Table 3), this was a substantial improvement from previous visits and a total of 6 straws of semen were frozen, and 3 - 4 straws were recommended per breeding. Two subsequent semen collections in the following month yielded adequate quality ejaculates and 2 additional doses of straws were cryopreserved.

Percentage of PGCs in serial ejaculates from the patient is summarized (Table 4). Quantification of PGCs was performed by a dual boarded (theriogenology and anatomic pathology) person, blinded to the case progression. Counts were performed in triplicate and then averaged. Results are reported as % of PGCs compared to mature sperm after counting 100 cells on the slide (e.g. out of 100 cells counted, 24 were PGCs and 76 were sperm, yielding a result of 24% PGCs).

**Table 3.** Sperm morphology after the designated rest period of 4 months

Normal morphology	Abnormal heads	Abnormal midpieces	Tailless	Proximal droplets	Distal droplets	Bent tails	Coiled tails
42%	5%	5%	18%	15%	0%	18%	1%

**Table 4.** Average percent of premature germ cells (PGCs) in serial ejaculates

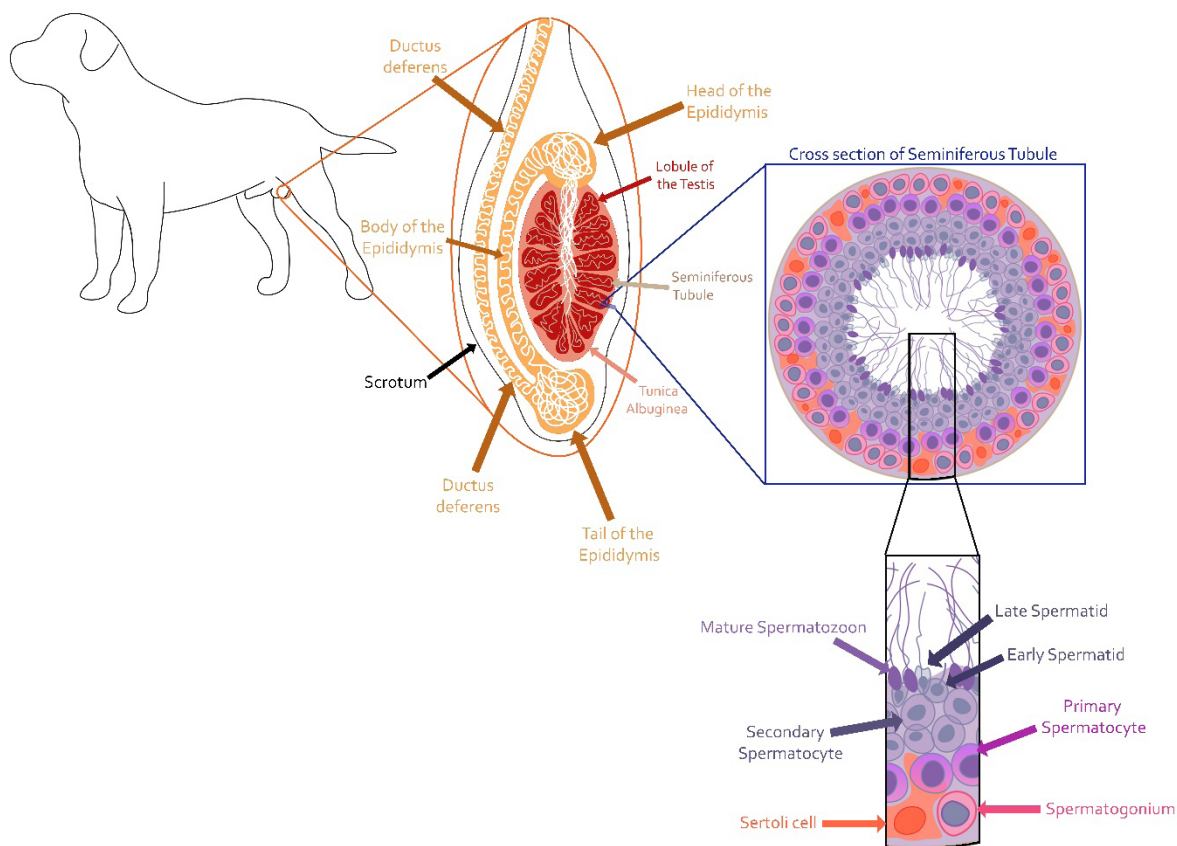
Date	PGCs
6/27/2018	24
7/19/2018	4
1/3/2019	1
2/7/2019	1
2/8/2019	0
2/14/2019	0
5/29/2019	5
6/21/2019	5

Although the patient’s spermiogram never entirely normalized, PGC counts, total sperm number, and morphology parameters improved considerably after removal from training activities. Even though it cannot be confirmed, heat stress during training is strongly suspected to have been the cause of testicular insult in this case. Scheduling semen collection during the patient’s noncompetitive season (~ 90 days after the last competition) allowed improved sperm health, facilitated cryopreservation, and yielded a positive outcome for this patient and client.

**Discussion**

Testis has endocrine and exocrine roles. Interstitial (Leydig) cells provide endocrine function in the testis synthesizing testosterone from progesterone in response to luteinizing hormone from the anterior pituitary. Sustentacular (Sertoli) cells support seminiferous tubules’ germinal epithelium, wherein the exocrine product (sperm) is produced. Process of sperm production is known as spermatogenesis. Spermatogenesis consists of spermatocytogenesis (differentiation of spermatogonia into spermatids) and spermiogenesis (further differentiation of spermatids into sperm). During these processes, spermatogonia mitotically divide to produce primary spermatocytes that undergo meiosis to eventually produce round spermatids within the seminiferous tubules. Spermatids then mature into sperm along the seminiferous tubules undergoing final maturation and storage within epididymis (Figure 3).

Within seminiferous tubules, there is a cycle of seminiferous epithelium and spermatogenic wave. The cycle of the seminiferous epithelium refers to synchronous development of a stage of the cycle, as defined by cellular associations present at a distinct location of the seminiferous tubule.



**Figure 3.** Schematic gross anatomy and microscopic representation of the process of spermatogenesis within testis (drawn by Jamie Douglas)

Cross-section of a particular stage of the seminiferous epithelium has multiple layers of germ cells, with each layer composed of sperm cell precursors of a distinct level of maturity. As these sperm cells mature, each successive stage of the cycle of the seminiferous epithelium results in maturing cells migrating toward the lumen of the seminiferous tubule. Spermatogenic wave refers to the dynamic change of a given stage of seminiferous epithelium along the length seminiferous tubule. This results in a constantly changing site for spermiation, or release of sperm, along the seminiferous tubule. Importance of cycle of the seminiferous epithelium and spermatogenic wave is that they provide continual sperm production that remains uninterrupted regardless of the frequency of ejaculation. Issues (e.g. heat stress) that result in injury to spermatogenic epithelium affect spermatogenesis via disruption in succession of sperm cell lines. This disruption in succession takes time to manifest within the ejaculate and is often the reason for evidence of insult not immediately visualized in the ejaculate. Similarly, effects of insult to seminiferous epithelium take time to be cleared from an ejaculate. Spermatogenesis is a process that occurs over 62 days in the dog,<sup>1,4</sup> needing a minimum of 62 days for all the effects of an injury to be cleared from the ejaculate.

Patient was presented for evaluation of fertility. On successive semen evaluations, the patient produced sperm with many head and midpiece defects in addition to the presence of unidentified round cells. Cytologic evaluation of the ejaculate can be completed by performing a simple smear (similar to a blood smear) using undiluted semen and Wright's Giemsa stain.<sup>1,4</sup> The smear should be assessed for white blood cells, red blood cells, bacteria, and for abnormal cells. Semen is not a sterile fluid, but excessive accumulation of white blood cells, blood, or bacteria can be indicative of inflammation or infection within the reproductive tract. If inflammation or infection is suspected, culture and sensitivity of the seminal fluid would be warranted. Blood, inflammatory cells, or bacteria in semen warrants for additional diagnostics to further assess health and fertility.

Unusual type of round cells identified in this case were later confirmed to be an abnormal sperm cell precursor, or PGC. Round cells identified in the ejaculate have 2 possible origins: nonspermatogenic or spermatogenic. Nonspermatogenic round cells include various epithelial cells, polymorphonuclear granulocytes, macrophages, and lymphocytes. Round cells of spermatogenic origin, as in this case, indicate severe disruption of spermatogenesis and appear in the ejaculate following damage of the seminiferous epithelium. Migration of germ cells into the lumen of the seminiferous epithelium is a highly ordered and complex event. Damage to seminiferous epithelium disrupts interconnecting bridges between developing germ cells. These disruptions result in premature release of excessive numbers of germ cells into the lumen of the seminiferous tubules, and ultimately, their release into the collecting ducts of the testis and later in the ejaculate.<sup>3</sup>

Lack of any known illness at presentation of a stud dog with suspected fertility issues warrants diagnostics beyond the standard breeding soundness examination. In this patient, diagnostic tests indicated that disruption of spermatogenesis had occurred, but provided no explanation for underlying cause

for the disruption. Of interest, this patient's physical examination was unremarkable except for an isolated incident of a slightly elevated rectal temperature during clinical examination. No history of previous illness was reported. For these reasons, an alternate explanation was pursued. Following the veterinarian's recommendation, the owner purchased a thermometer for surveillance of rectal temperature while working. This allowed identification of rectal temperatures of 107 - 108°F in the patient following only 5 - 7 minutes of work via 2 controlled retrieves (light work). For perspective, a working retriever would be conditioned to perform for longer periods (20 - 30 minutes) of time without substantial increases in rectal temperature following short-duration exercise. Confirmation of those temperatures leads us to believe that severe hyperthermia was occurring during routine training contributing to testicular thermal injury. Additionally, the patient's geographical location of training (southeastern US) and high drive to perform required tasks contributed to the likelihood of hyperthermic episodes. Geographical location and increased environmental temperature can be further supported by reviewing the percentage of PGCs in the ejaculate. Months with higher ambient temperatures correlated with increased PGC counts in the ejaculate.

In bulls, prolonged scrotal hyperthermia resulted in severe disruption of spermatogenesis.<sup>5</sup> Bulls that experienced scrotal hyperthermia had a high number of sperm defects resulting in head and midpiece abnormalities. Short-term scrotal insulation in dog had no major effects on spermatogenesis; however, long-term exposure to increased testicular temperature has not been evaluated.<sup>6</sup> Because this patient is a working dog in a humid, subtropical climate, it is likely that the patient sustained periods of elevated body temperature that resulted in testicular hyperthermia and disrupted spermatogenesis. Due to the training and activities performed, the patient may have overwhelmed the process by which the body thermoregulates testicular temperature, thus sustaining thermal damage of the seminiferous epithelium. Damage to vulnerable cells of the germinal epithelium within the testis would result in the severe defects observed in the patient's spermograms.

### Learning Points

- A thorough understanding of the process and duration of spermatogenesis is required to make appropriate clinical decisions in cases of suspected male infertility.
- This case illustrated that routine spermogram allows the practitioner to identify atypical cells and critically evaluate an abnormality associated with spermatogenesis.
- Evaluation of disruption in spermatogenesis based on spermograms enables clinicians to make appropriate decisions to solve the clinical problem.

### Conflict of interest

Authors have no conflict of interests to disclose.