

Disorders of sexual development: a case of XX sex reversal in a mixed breed dog negative for SRY (sex-determining region on the Y chromosome) gene



Kelsey Martin,^a Agata Parsons,^b Greg Burns,^a Gerrit Bouma,^b Fiona Hollinshead^a

^aDepartment of Clinical Sciences, ^bDepartment of Biomedical Sciences

College of Veterinary Medicine and Biomedical Sciences

Colorado State University, Fort Collins, CO

Abstract

An 8-month mixed breed dog (from shelter) was evaluated for its abnormal external genital (enlarged os clitoris protruding externally from the vulva) condition. Dog had phenotypic female appearance. Testicular-like tissue was removed via laparoscopy-assisted gonadectomy. Genotype was determined using blood and gonadal tissue (via histology and immunohistochemistry). Dog had XX chromosomes and was negative for SRY (sex-determining region on the Y chromosome) gene.

Keywords: Phenotypic sex, antimüllerian hormone, sex reversal

Background

Normal mammalian sexual development involves chromosomal sex (XX or XY [determined at fertilization]), followed by development of gonadal sex (ovary or testis), and finally expression of phenotypic sex (internal reproductive tract and external genitalia).¹ Errors in these 3 stages resulted in disorders of sexual development (DSDs), manifesting in a variety of anatomical and physiological abnormalities in affected individuals.² Generally, DSDs are classified based on the incongruencies that exist among the stages of sexual development. Individuals that demonstrate a discrepancy between their chromosomal and gonadal sex development had a sex reversal (SR) phenotype and are considered either XX male or XY female.³ These SR individuals can be either positive or negative for sex-determining region on the Y chromosome (SRY) gene that regulates gonadal differentiation. Absence of SRY gene causes development of ovaries and a female phenotype. Presence of SRY gene results in activation of genes, including SOX9, triggering 'male' development pathway toward formation of testes with internal and external masculinization.⁴ Reports of XY sex reversal in dogs are rare.^{5,6} Conversely, reports of XX sex reversal in dogs are more common.⁷ Regardless, it is important for practitioners to be aware of this clinical presentation in addition to understanding the development of DSDs and use proper nomenclature associated with these syndromes to systematically diagnose and appropriately manage SR clinical cases.

Case presentation

History

An 8-month intact mixed breed dog was presented to the Small Animal Reproduction Service at the Colorado State University Veterinary Teaching Hospital for evaluation of abnormal external genitalia. Referring veterinarian identified the abnormality while managing the dog for a urinary tract infection after hematuria (observed by the owners shortly after adoption). Besides hematuria, other presenting clinical signs included vulvar discharge and perivulvar dermatitis. Current owners reported absence of estrous or intact male behaviors. Previous owners confirmed that the dog never had any surgery (reproductive alteration or otherwise). There was no evidence of underlying endocrinopathy (e.g. hyperadrenocorticism leading to clitoral hypertrophy⁸) nor was exposure to androgens or progestins^{9,10} during pregnancy or thereafter.

Physical examination, vaginal cytology, hematology, serum biochemistry

Dog had female phenotype appearance with normal vulvar conformation. However, had an enlarged clitoris (Figure 1) with a palpable bony structure consistent with os clitoris. Clitoral enlargement was noticed along the ventral aspect of vulva that protruded ~ 2 cm from the vulvar cleft when the patient was in standing position. Under sedation, it was determined via urethral catheterization that urination occurred from within the vulva just cranial to the base of the clitoris, and not from the protruding os clitoris. There were no palpa-

ble testes nor scrotal structures. Internal reproductive structures were not identifiable via abdominal ultrasonography.

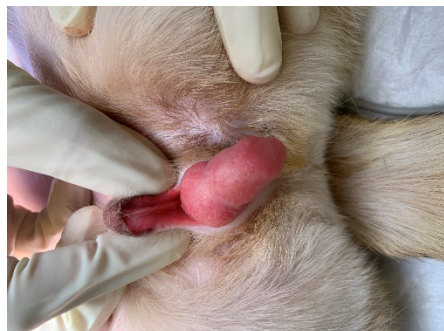

Figure 1. Externally protruding hyperplastic os clitoris

A cotton tipped plastic handle swab was used to obtain a vaginal smear. Swab was rolled onto a glass microscope slide that was then air dried and stained using a simple modified Wrights-Giemsa stain (Diff-Quik). Vaginal smear was evaluated under light microscopy (100 - 200 x magnification). Predominant (> 90%) cells were parabasal cells, indicating lack of estrogenic influence. Complete blood count and serum biochemistry profiles were within normal canine reference ranges.

Owners declined further tests (e.g. serum antimüllerian hormone) and surgical options for os clitoris removal, but elected laparoscopic-assisted gonadectomy.

Gonadectomy

Patient was premedicated with 0.02 mg/kg atropine sulfate (Atropine Sulfate Injection, West Ward, Eatontown, NJ), 0.03 mg/kg acepromazine (Acepromazine Maleate Injection, VetOne, Boise, ID) and 0.05 mg/kg hydromorphone (Hospira Inc., Lake Forest, IL); all were given intramuscularly. Anesthesia was induced with 2 mg/kg ketamine (Ketaset®, Zoetis Inc, Florham Park, NJ) and 2 mg/kg propofol (Zoetis, Kalamazoo, MI) given intravenously. General anesthesia was maintained with isoflurane (Akorn Animal Health, Lake Forest, IL) in oxygen. A 2-cm ventral midline incision was made just caudal to the umbilicus and a single incision laparoscopic surgical port was placed into the abdomen to allow insufflation with CO₂ to a pressure of 10 mm Hg. A zero-degree laparoscope was inserted into 1 of the ports and the interior of the abdomen was explored. Left gonad was first visual-

ized and grossly appeared like testis. Using forceps and Ligasure™, the tubular structure associated with the gonad (presumed to be the ductus deferens and pampiniform plexus) were ligated. Vasculature and presumed ductus deferens on the right-hand side was followed into the inguinal ring and the remaining gonad was identified via deep external palpation. Using electrocautery, a 2 cm incision above the inguinal ring (where the testis-like gonad was located) was made and closed castration was performed. Abdominal cavity was examined before closure to confirm absence of ovaries, ovotestes, uterine tubular structure(s) or prostate. All incisions were closed in a standard, multiple layer fashion and there were no complications. Patient's recovery from anesthesia was uneventful and 2.2 mg/kg carprofen (Rimadyl®, Zoetis) was given subcutaneously for postoperative pain management.

Six months following surgery, a follow up phone consultation with the owner revealed that the clitoral enlargement had not reduced in size. There was no vulvar discharge or perivulvar dermatitis nor clitoral enlargement causing any irritation or distraction to the patient. Additionally, urination was reported to be normal.

Diagnosis

A case of DSD was suspected¹¹ and appropriate tests were conducted (e.g. immunochemical localization of antimüllerian hormone [AMH]¹²). Histology of gonadal tissue (Figure 2) revealed that the architecture of the tissue was consistent with hypoplastic testicular tissue (Figure 3). Empty seminiferous tubules lined by Sertoli cells were noticed in both testes; however, testes had no maturing germ cells nor obvious signs of active spermatogenesis. Interstitial tissue of testes had Leydig cells and epididymides had empty tubules lined with columnar epithelium. Gonal tissue was positive for AMH (Figure 4), confirming functional Sertoli cells (low testosterone concentrations observed in hypogonadism¹³).

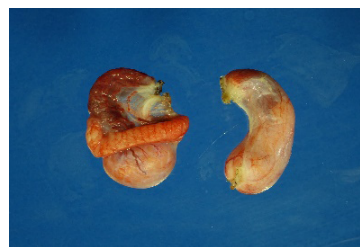

Figure 2. Gross image of the gonadal tissue removed at surgery

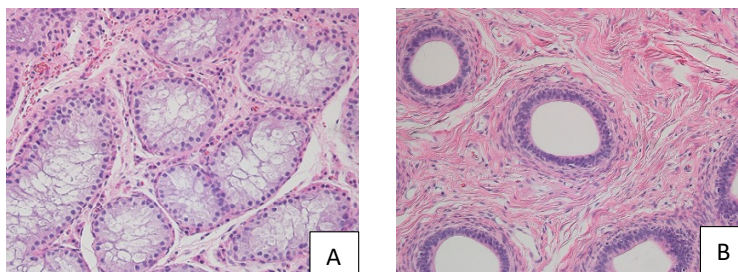


Figure 3. Hematoxylin and eosin-stained sections of testis (A) and epididymis (B); note absence of maturing germ cells in seminiferous tubules and normal epididymal epithelium with no sperm (200 x magnification).

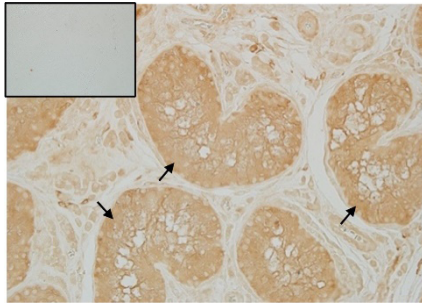


Figure 4. Immunolabeling for AMH (black arrows) within the seminiferous tubules containing Sertoli cells; note negative control (small insert) without primary antibody.

Chromosomal sex (i.e. XX versus XY) PCR was determined via amplifying¹⁴ *AMELOGENIN* (*AMEL*) gene from genomic DNA isolated from blood (Qiagen DNeasy Blood & Tissue Kit). Both X and Y chromosomes were positive for *AMEL* and their gene length polymorphism allowed for genetic sex identification. PCR was performed using Platinum™ II Taq Hot-Start DNA Polymerase (Invitrogen), with 0.5 µl of the *AMELX/AMELY* primers (5 µM), and cycle conditions 95 °C for 4 minutes, 95 °C for 30 seconds, 55 °C for 30 seconds, and 72 °C for 20 seconds, with the last 3 steps repeated 35 times, followed by a final step of 72 °C for 10 minutes. PCR amplification using *AMELX* (on the X chromosome) and *AMELY* (on the Y chromosome) specific primers yielded a 215 bp amplification product for *AMELX* and 247 bp for *AMELY* (Figure 5). Furthermore, in a separate PCR assay, 2 PCR primer sets were designed to amplify a 350 or 480 bp fragment of canine *SRY* gene (Table) to determine if *SRY* gene was present in the DNA.

PCR analysis of DNA isolated from a known male dog was positive for *SRY* (Figure 6). PCR cycle conditions for amplification of *SRY* were: 95 °C for 4 minutes, 95 °C for 30 seconds, 60 °C for 30 seconds, and 72 °C for 15 seconds, with the last steps repeated 40 times, followed by a final step of 72 °C for 1 minute. *SRY* was not detected in the genomic DNA isolated from the patient. This finding suggested that alternative and unknown non*SRY*-mediated mechanism(s) might have occurred, leading to testes development.¹⁵

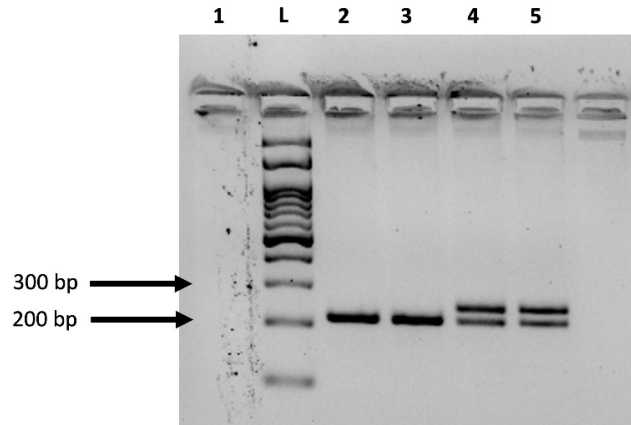


Figure 5. Amplified bands represent Amelogenin (*AMEL*); bottom band is *AMEL* present on the X chromosome (215 bp), and the top band is *AMEL* present on the Y chromosome (247 bp). Lane 1: H₂O (negative control). Lane 2 & 3: genomic DNA from the hermaphrodite dog. Lanes 4 & 5: genomic DNA from a known male (XY) dog. L = 100 bp ladder.

Table. Primer sequences and amplicon sizes generated by PCR amplification

Name	Primer Seq (5' to 3')	Amplicon size (bp)
<i>AMELX</i>	ATAATGACAAAGAAAACATGAC	215 (<i>AMELX</i>)
<i>AMELY</i>	CTGCTGAGCTGGCACCAT	247 (<i>AMELY</i>)
<i>DogSRY1-F</i>	GGTGCAGCGGTACAACAAAA	350
<i>DogSRY1-R</i>	TTCCGACGAGGTCGGTATTT	
<i>DogSRY2-F</i>	GGTGCAGCGGTACAACAAAA	482
<i>DogSRY2-R</i>	CGTGTGTGTGCAGCCCTACT	




Figure 6. Amplified bands represent *SRY*

Discussion

Diagnosis (SRY-negative XX male with testes) was confirmed by histomorphological evaluation of the gonads, determination of the chromosomal sex and absence of the SRY gene by PCR analysis. Cases of SRY-negative XX SR were most commonly reported in purebred dogs, suggesting heritability most often as an autosomal recessive trait.^{16–18} However, in this case of a mixed breed dog, the etiology was most likely a spontaneous event, due to either a genetic gain-of-function mutation or loss-of-function mutation that altered expression of key regulatory genes necessary for female or male sexual development. It is possible that overexpression of the SOX9 gene had a key role in testicular differentiation and development in the formation of testes in this case. Duplications within the SOX9 gene, often in the promoter region, was the most common mutation leading to SRY-negative XX SR phenotypes in dogs.^{4,19} Therefore, overexpression of the SOX9 gene might have been a key factor for testes induction in the absence of SRY. However, mutations in this gene are not always the cause of SRY-negative XX SR, and inactivating mutations of ovarian determining genes such as RSPO1 or CTNNB1 could be responsible for the observed external female phenotype in this case. Further genomic analyses are required to better understand what genetic factors for testes induction may exist.³

Clinically, the challenge with DSD cases is that individuals can present with a wide range of anatomical abnormalities including ambiguous external genitalia, clitoral enlargement, hypospadias, and cryptorchidism. These anatomical abnormalities can then cause secondary clinical complications such as vaginitis, vulvar discharge, and urinary tract infections. Anatomical and clinical developmental abnormality type depends on the degree of phenotypic masculinization. This is based on the amount of functional testis that developed and may vary depending on the quantity and timing of testicular secretions necessary to masculinize internal and external genitalia.²⁰ Furthermore, testosterone concentrations produced are insufficient in quantity or its conversion to dihydrotestosterone by 5 α -reductase is impaired during the critical period for androgen-dependent masculinization, internal and external genitalia will fail to masculinize in whole or in part, as with this case.

Approximately 90% of XX sex reversal cases occur with bilateral ovotestes and the remainder (10%) with bilateral testes. However, there were some cases that occasionally presented with an ovary and ovotestis or an ovotestis paired with a testis.³ In this case, despite having 2 testes, the patient had phenotypic female appearance with no anatomical evidence of a scrotum or prepuce, an unusual presentation. Primary clinical concern was the exposed (presumed hypertrophied) clitoris and secondary vaginitis associated with a vulvar discharge.

Normal sexual development is a process that is highly dependent on the timing of events plus the molecular and hormonal expression of karyotype in adequate and appropriate amounts. Delayed or insufficient quantity of AMH secretion in XY males during the critical period (regression of Mullerian duct) result in persistence of all or part of the Mullerian duct derivatives (oviducts, uterus, cervix, cranial vagina).¹⁸ This XX patient developed testes with functional (able to produce

AMH) Sertoli cells that apparently suppressed the emergence of Mullerian duct derivatives.

Learning Points

- Determine the chromosomal, gonadal, and phenotypic sex of a suspected DSD patient.
- Assess the effect abnormal reproductive anatomy on the dog's health and welfare.
- Implement a welfare-orientated management strategy that would alleviate the secondary clinical signs caused by clitoral hyperplasia.

Conflict of interest

None to declare.

Acknowledgement

Authors thank Kelsey Tofany for excellent technical assistance (clinical examination and blood withdrawal) and patient management.

References

1. Meyers-Wallen VN: Inherited abnormalities of sexual development in dogs and cats. In: Concannon PW, England G, Verstegen III J, et al: editors. *Recent Advances in Small Animal Reproduction*. 1st edition, United States; International Veterinary Information Service: 2001.
2. Poth T, Breuer W, Walter B, et al: Disorders of sex development in the dog-Adoption of a new nomenclature and reclassification of reported cases. *Anim Reprod Sci* 2010;121:197-207.
3. Parma P, Veyrunes F, Pailhoux E: Sex reversal in non-human placental mammals. *Sex Dev* 2016;10:326-344.
4. Albarella S, de Lorenzi L, Rossi E, et al: Analysis of XX SRY-negative sex reversal dogs. *Animals* 2020;10:1-13.
5. Chaffaux S, Cribiu EP: Clinical, histological and cytogenetic observations on nine intersex dogs. *Genet Sel Evol* 1991;23:81-84.
6. Kang JT, Kim HJ, Oh HJ, et al: SRY-positive 78, XY ovotesticular disorder of sex development in a wolf cloned by nuclear transfer. *J Vet Sci* 2012;13:211-213.
7. Yoon H, Han SH, Kim J, et al: Urogenital anomalies and urinary incontinence in an English Cocker Spaniel dog with XX sex reversal. *J Vet Intern Med*. 2018;32:1166-1171.
8. Purswell BJ, Kolster KA: Surgical disease of the vulva and vagina. In: Bojrab MJ, Monnet E: editors. *Mechanisms of Disease in Small Animal Surgery*. 3rd edition, Jackson; Teton NewMedia: 2015.
9. Curtis EM, Grant RP: Masculinization of female pups by progestogens. *J Am Vet Med Assoc* 1964;144:395-398.
10. Sokolowski JH, Zimbelman RG: Canine reproduction: effects of multiple treatments of medroxyprogesterone acetate on reproductive organs of the bitch. *Am J Vet Res* 1974; 35:1285-1287.
11. Sumner SM, Grimes JA, Wallace ML, et al: Os clitoris in dogs: 17 cases (2009-2017). *Can Vet J* 2018;59:606-610.
12. Alm H, Bodil SH: Identifying ovarian tissue in the bitch using anti-Müllerian hormone (AMH) or luteinizing hormone (LH). *Theriogenology* 2018;106:15-20.

13. Grinspon RP, Bedecarrás P, Ballerini MG, et al: Early onset of primary hypogonadism revealed by serum anti-Müllerian hormone determination during infancy and childhood in trisomy 21. *Int J Androl* 2011;34:e487-e498.
14. Yan S, Bai C, Li Y, et al: Sex identification of dog by PCR based on the differences in the AMELX and AMELY genes. *Anim Genet* 2013;44:604-607.
15. Meyers-Wallen VN: Gonadal and sex differentiation abnormalities of dogs and cats. *Sex Dev* 2012;6:46-60.
16. Melniczek JR, Dambach D, Prociuk U, et al: SRY-negative XX sex reversal in a family of Norwegian Elkhounds. *J Vet Intern Med* 1999;13:564-569.
17. Campos M, Moreno-Manzano V, García-Roselló M, et al: SRY-negative XX sex reversal in a French Bulldog. *Reprod Dom Anim* 2011;46:185-188.
18. Meyers-Wallen VN, Schlafer D, Barr I, et al: SRY-negative XX sex reversal in purebred dogs. *Mol Reprod Dev* 1991;53:266-273.
19. Rossi E, Radi O, de Lorenzi L, et al: Sox9 duplications are a relevant cause of SRY-negative XX sex reversal dogs. *PLoS ONE* 2014;9:e101244.
20. Schlafer DH, Valentine B, Fahnestock G, et al: A case of SRY-positive 38,XY true hermaphroditism (XY sex reversal) in a cat. *Vet Pathol* 2011;48:817-822.