

Accuracy of radiographic fetal count in ewes

Camille Ogdon, Charles Estill, Kelly Van Scoyk and Lauren Newsom
Carlson College of Veterinary Medicine, Oregon State University, Corvallis, OR, USA

Abstract

Accurate fetal count is important for farm animal species as the number of fetuses can affect management decisions in both research and production settings. Documented methods of pregnancy diagnosis include radiography, progesterone assays, transrectal palpation, and transrectal and transabdominal ultrasonography; however, there is variability in fetal count accuracy with each of these methods. Abdominal radiography evaluation in 13 pregnant ewes among observers of various skill levels was compared retrospectively with the known number of fetuses determined using computed tomography. Overall accuracy using abdominal radiography across skill levels for determining fetal counts correctly was 79%. Accuracy decreased as the number of fetuses increased, with accuracies for singleton, twin, and triplet pregnancies being 92, 72, and 50%, respectively. Additionally, observer experience was inversely related to radiographic fetal count accuracy.

Keywords: Sheep, pregnancy, radiograph, ultrasound, abdominal computed tomography, fetal count, litter size, pregnant ewe, fetal skeleton

Introduction

Use of radiographs to determine fetal counts is a common practice in veterinary medicine because of their wide availability and affordability, particularly in patients who are small enough for abdominal radiography. Many aspects of pregnancy can be evaluated using radiographs, including fetal size, position, number, and fetal viability.¹ There are several practical methods of pregnancy diagnosis in ewes, including radiography, hormonal assays, pregnancy-associated protein assays, and ultrasonography.² Although only radiography, progesterone assays, and ultrasonography have the capability to discern between single and multiple fetuses; varying degrees of accuracy for absolute number of fetuses have been reported for these modalities. Having an accurate radiographic fetal count can be important to sheep producers with valuable breeding animals, as larger litter sizes may result in increased production, although litters that are too large may put the ewe's health at risk. At our institution, inaccurate small ruminant radiographic fetal counts are not uncommon regardless of observer experience or specialty training. Litter size is important for research purposes where a specific number of fetuses may be desired for subjects to be included or excluded in a study. Difficulty performing abdominal radiography in sheep is mostly because of overall patient size necessitating increased radiographic exposure in order to produce radiographs with clearly identifiable fetal structures. Superimposition with the abdominal organs, particularly the rumen and colon, creates a challenging situation when attempting to identify and accurately count fetal skeletal structures.

Radiographs are a practical, affordable, and widely available method to determine pregnancy status and to attempt fetal counts in small ruminants whose average pregnancy length is between 144 and 151 days. Mineralization of the fetal skeleton can be detected radiographically as early as 41 days with components of the skull, ribs, and hindlimbs visible.³ Radiographic pregnancy diagnosis can be as high as 100%, and radiographs are reported to be 90% accurate in determining fetal counts after day 70–90 of pregnancy.^{2,4} Full fetal skeletons have been radiographically identified as early as day 58 of pregnancy in goats.⁴ If there is no observable mineral skeletal formation of a fetus by day 75 of pregnancy, the doe is considered not pregnant.⁴ Though fetal count accuracy increases later in pregnancy due to increased fetal size and mineralization, there are occasions when an accurate count may be desired earlier in pregnancy.

Serum progesterone concentrations were higher in ewes with multiple litter sizes compared to singleton pregnancies. However, there is considerable overlap between serum concentrations for different litter sizes and reliability for this test is low. In addition, there is no evidence that this test can determine an exact count of fetuses beyond the differentiation between none, one, and multiple fetuses.⁵

Two types of transabdominal ultrasonographic imaging are available to assist with pregnancy diagnosis and prediction of fetal number, including B-mode ultrasonography alone or in combination with color Doppler. B-mode ultrasonography with

color Doppler is the most accurate method to diagnose pregnancy, with up to 100% accuracy when performed >60 days post-breeding.⁶ Accuracy was 100% in diagnosing pregnancy as early as day 39.⁷ When used by an experienced sonographer, color Doppler ultrasonography had 93% accuracy for distinguishing between single or multiple fetuses when performed between day 80 and 95 of pregnancy⁸; however, overall accuracy decreased as litter size increased. Accuracy was 31% for detecting triplet pregnancies and an overall accuracy of 78% for all types of pregnancies.⁷ Real-time B-mode transabdominal ultrasonography can be used to determine fetal counts after day 50 of pregnancy, but with an unknown degree of accuracy.⁹ Transrectal abdominal sonography has also been used successfully to determine pregnancy status, though this method was not reliable in determining an accurate fetal count when performed in the first 25 days of pregnancy and when multiple fetuses were present.²

Apparently, computed tomography (CT) use for diagnosis of pregnancy and fetal counts in small ruminants has not been reported. CT is often cost prohibitive and geographically unavailable for most producers; however, this imaging modality can be used to determine fetal counts quickly and accurately. CT also results in increased radiation exposure to the developing fetus and mother. There is evidence that increased radiation exposure in early pregnancy (\leq day 30) can inhibit development of limbs in sheep¹⁰; however, there is limited information regarding the safe and acceptable dose of radiation in fetal sheep.

The first objective was to determine the accuracy of radiographic fetal counts in pregnant sheep among observers of various skill levels. The second objective was to determine if there is a correlation in accuracy between novice and experienced observers. We hypothesized that increased experience increases radiographic fetal count accuracy and with increased fetal numbers, radiographic fetal count accuracy decreases.

Materials and methods

Digital standing lateral abdominal radiographs of 13 healthy, pregnant ewes between day 76 and 90 after breeding were

evaluated retrospectively for determination of fetal number. Only ewes that had abdominal radiographs in our institutions Picture Archiving and Communication System (PACS) system (NovaRad, version 8.7.11, NovaRad Corporation, American Fork, UT) and a definitively known number of fetuses determined either via CT, cesarean surgery, or necropsy, were considered. Ewes were identified by searching both our PACS and Hospital Information System (HIS) systems. Radiographs were anonymized before evaluation via our PACS system. Participants were blinded to the definite number of fetuses for each ewe and previous imaging reports. Radiographs were evaluated by a board-certified radiologist, a 1st-year radiology resident, a 4th-year veterinary student, and a board-certified theriogenologist. Interpretation of radiographs relied on existing reviewer experience, with no guidelines in place for how to interpret radiographs. Fetal counts were recorded in separate Microsoft Excel sheets for each observer and compared to known accurate fetal counts for each ewe. Percent accuracy was calculated by dividing the number of radiographically observed fetuses by the definite number of fetuses present, multiplied by 100. Percent accuracy was calculated for each individual observer and each number of fetuses (singleton, twins, and triplet). Overall percent accuracy for all observers and for each number of fetuses was also calculated.

Results

Thirteen ewes that had abdominal radiographs and definite fetal number determined via CT were included. Radiographic interpretation results of each observer and for each ewe, in addition to the definite fetal count confirmed via CT are provided (Table 1). Overall accuracy was 79%, ranging between 67 and 92% depending on the observer (Table 2). Overall accuracies for singleton, twin, and triplet pregnancies were 92, 72, and 50%, respectively (Table 2). Seven out of 13 ewes had at least 1 observer report an incorrect fetal number, and 6/13 cases reported an inaccurately low fetal count. Ewe 13 had 2 confirmed fetuses, although only 50% of the observers accurately reported this number (Figure 2). Only 1 case (ewe 12) had 3 fetuses that were correctly reported by all reviewers (Figure 1). In 1 case (ewe 8), a single observer reported a radiographic fetal count higher than the definite

Table 1. Radiographic interpretation by each observer

Ewe	Number of fetuses identified on radiograph				Confirmed count
	Radiologist	Radiology resident	Veterinary student	Theriogenologist	
Ewe 1	2	1	2	2	2
Ewe 2	1	1	1	1	2
Ewe 3	2	2	2	1	2
Ewe 4	2	2	2	2	2
Ewe 5	1	1	1	1	3
Ewe 6	2	2	2	2	2
Ewe 7	1	2	2	2	2
Ewe 8	1	1	1	2	1
Ewe 9	1	1	1	1	1
Ewe 10	1	1	1	1	1
Ewe 11	2	2	2	2	2
Ewe 12	3	3	3	3	3
Ewe 13	1	2	2	1	2

Table 2. Calculated accuracy (%) of interpretations

	Radiologist	Radiology resident	Veterinary student	Theriogenologist	Overall accuracy
Accuracy	75	83	92	67	79%
Singleton accuracy	100	100	100	67	92%
Twin accuracy	63	75	88	63	72%
Triplet accuracy	50	50	50	50	50%

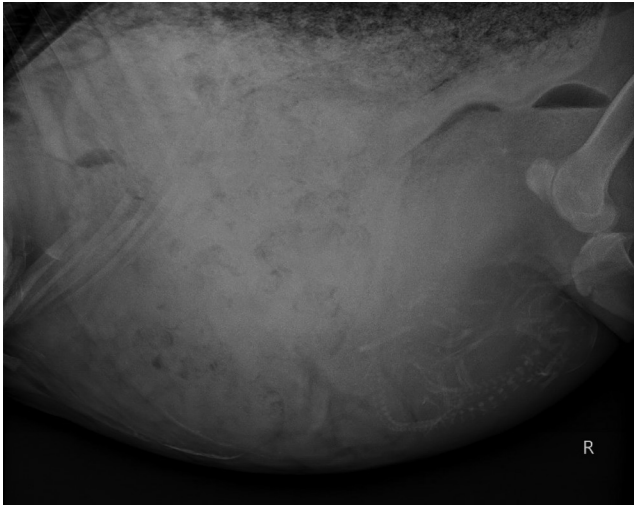


Figure 1. Radiograph of a triplet pregnancy of ewe 12 (Table 1) with 3 fetuses correctly identified by all reviewers

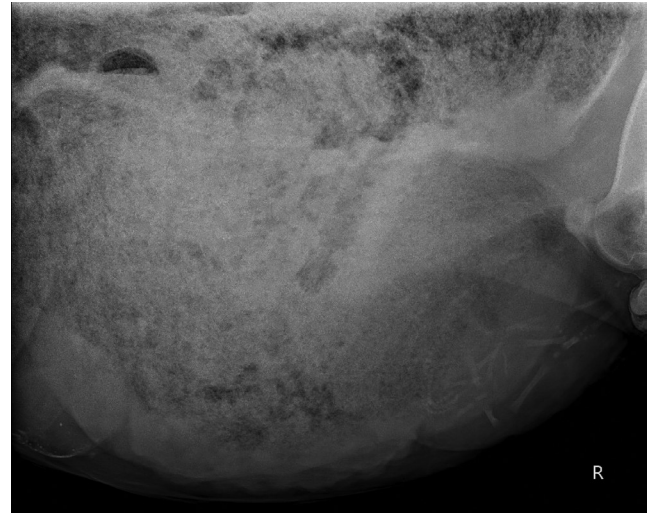


Figure 3. Radiograph of a confirmed triplet pregnancy of ewe 5 (Table 1) with only 1 fetus identified by all reviewers

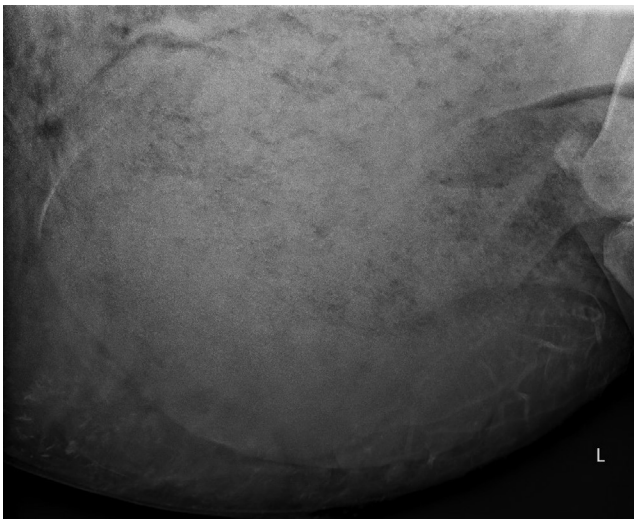


Figure 2. Radiograph of a twin pregnancy of ewe 13 (Table 1) correctly identified by 50% of the reviewers

number. Ewe 5 was reported by all reviewers to only have 1 fetus (Figure 3); however, she had a definite fetal count of 3. Surprisingly, accuracy decreased with increased observer experience with the 4th-year veterinary student having the highest overall accuracy at 92% and the observer with the most years of clinical experience had the lowest overall accuracy at 67%.

Discussion

Based on our findings, radiographic fetal count accuracy in sheep is only 79% across observers regardless of the number of fetuses, although increased litter size was associated with reduced accuracy for all observers. Seven out of 13 cases (53.8%) had at least observer report an inaccurate fetal count, most of which (6/7) were inaccurately low. This is likely in part due to summation with intra-abdominal organs and overall increased size of the ewe resulting in reduced radiographic detail.

Only 2/13 ewes had triplet pregnancies. Radiographic fetal count in ewe 12 (with triplets) was correctly evaluated by all observers, regardless of skill level. Ewe 5 was reported by all reviewers to only have 1 fetus; however, CT examination identified 3 mineralized fetuses. On reevaluation of the radiographs from this ewe, a single, ill-defined spine was observed to be summing with the colon that was full of formed feces. A third fetus was not radiographically detectable in this ewe. Without the knowledge of three fetuses in this case (confirmed later via CT), experienced observers were unconvinced that the mineral summing with the colon was consistent with a fetus. Hence our hypothesis that increased fetal number reduces radiographic fetal count accuracy is accepted; however, further evaluation with higher sample size is necessary.

Sonography and color Doppler are commonly used by experienced practitioners to confirm pregnancy in small ruminants, and color Doppler ultrasonography is up to 93% accurate

for determining whether 1 or multiple fetuses are present.⁸ However, similar to radiography, sonographic accuracy decreased as litter size increased and sonography was only 31% accurate for detecting triplet pregnancies.⁷ Ultrasonographic evaluation does require skill and experience and as a result is subject to human error. Modern radiography is predominantly a digital modality, and images can be shared and evaluated by observers of various skill levels in various geographic locations as needed for consultation. At our institution, radiography is used primarily for research due to concern for unacceptable sonographic count accuracy if ≥ 2 are present, particularly when differentiation between twins and triplet pregnancies is absolutely necessary for inclusion or exclusion in a study. CT findings confirmed that radiography is unreliable to differentiate between twins and triplet pregnancies.

Interestingly, radiographic fetal count accuracy was inversely related to observer experience and training, with the 4th-year veterinary student having the highest overall accuracy at 92%. Therefore, our hypothesis that increased experience leads to improved observer accuracy of radiographic fetal counts is rejected. There are several possible reasons, including the low overall number of ewes, random chance or a fundamental difference in how the observers evaluated the studies. For example, on evaluation of pregnant ewe radiographs, 2 observers may convincingly notice 1 fetus and question a second fetus. One observer may report only 1 fetus as this is the number they are certain of whereas the second observer reports 2 fetuses due to the concern of missing a fetus. The authors believe that this fundamental difference in observer interpretation reflects the realities of clinical practice, clinician preference, and overall confidence in personal skills. In this study design, an option for documenting questionability of a fetus was not considered and it was required that each observer make a final decision about fetal number. It is possible that creating an additional option during radiographic evaluation for documenting a questionable fetus may improve overall accuracy numbers and agreement among observers. The small number of ewes studied is a limitation; repeating with a larger number of ewes may yield different results. Performing repeat radiographs at various stages of pregnancy, including late pregnancy, may help to determine time points at which radiographs are most useful and most accurate.

Ionizing radiation is a veterinary occupational safety hazard created by radiography and CT, but not with sonography. In all situations, the benefit of obtaining diagnostic quality images should outweigh the risk of ionizing radiation exposure to people and animals involved in the imaging study. Increased patient size requires an increased radiation dose to obtain diagnostic quality radiographs. This in turn results in increased patient and human exposure due to scatter radiation. Majority of small ruminant radiographs at our institution are performed standing with a sedated patient and people present in the room to hold the patient and the cassette. Regular training and rules are in place to reduce radiation exposure to personnel involved in each study. Furthermore, personnel wear leaded devices (apron, thyroid shield, gloves, and eyeglasses) to protect from scatter radiation. Personnel are also instructed to increase their distance from the primary beam and the patient by holding their arms straight and to avoid having any of their own anatomy within the primary beam.

CT imaging of sedated small ruminants at our institution is a common practice with sick and injured animals. This modality is priced competitively and provides

exponentially more information compared to radiography. CT is a superior modality in reducing human exposure to ionizing radiation. In either radiography or CT, there is ionizing radiation exposure to ewe and fetus. According to the National Council on Radiation Protection and Measurements and the Environmental Protection Agency, the average radiation exposure from an abdominal radiography study and abdominal CT study in a person is 0.7 and 10 millisieverts, respectively.¹¹ This equates to a 14–15 fold difference in radiation dose to the ewe and fetus when a CT scan is performed rather than radiography. Risk to a fetus when exposed to ionizing radiation depends both on the dose of radiation and the fetal age at imaging.¹² Human fetal radiation dose from an abdominal CT study ranged from 1.3 to 35 milligray.¹² In people, a fetal radiation dose exposure between 10 and 20 milligray could increase the risk of childhood leukemia 1.5–2 fold above the existing rate of 1 in every 3,000 children.¹² Radiation exposure risk to sheep fetus is currently unknown, but could have similar risks to what are reported for people.

Conclusion

It is important to inform producers or researchers requesting accurate fetal counts that radiographs may yield inaccurately low numbers. If accurate fetal numbers are critical for production or research decisions, other noninvasive imaging techniques (e.g., CT), can be considered to obtain a definite number as long as the benefits outweigh the risks.

Acknowledgement

The authors thank the Imaging Technicians of Oregon State University's Diagnostic Imaging Department for obtaining diagnostic studies.

Conflict of interest and funding

None to declare. Research project did not receive any specific grant from funding agencies (public, commercial, or not-for-profit sectors).

References

1. Thrall DE: The uterus, ovaries, and testes. In: Textbook of veterinary diagnostic radiology. 6th ed. St Louis, MO: Elsevier; 2013, pp. 758–761.
2. Karen A, Kovács P, Beckers JF, et al: Pregnancy diagnosis in sheep: review of the most practical methods. *Acta Vet Brno* 2001;70: 115–126. doi: 10.2754/avb200170020115
3. Wenham G: A radiographic study of early skeletal development in foetal sheep. *J Agric Sci (Tor)* 1981;96:39–44. doi: 10.1017/S0021859600031853
4. Barker CAV, Cawley AJ: Radiographic detection of fetal numbers in goats. *Can Vet J* 1967;8:59–61.
5. Chauhan FS, Waziri MA: Evaluation of rectal-abdominal palpation technique and hormonal diagnosis of pregnancy in small ruminants. *Indian J Anim Reprod* 1991;12:63–67.
6. Ishwar AK: Pregnancy diagnosis in sheep and goats: a review. *Small Rumin Res* 1995;17:37–44. doi: 10.1016/0921-4488(95)00644-z.
7. Jones AK, Gately RE, McFadden KK, et al: Transabdominal ultrasound for detection of pregnancy, fetal and placental

- landmarks, and fetal age before day 45 of gestation in the sheep. *Theriogenology* 2016;85:939–945. doi: 10.1016/j.theriogenology.2015.11.002
8. Fukui Y, Kobayashi M, Tsubaki M, et al: Comparison of two ultrasonic methods for multiple pregnancy diagnosis in sheep and indicators of multiple pregnant ewes in the blood. *Anim Reprod Sci* 1986;11:25–33. doi: 10.1016/0378-4320(86)90099-0
 9. Lone SA, Gupta SK, Kumar N, et al: Recent technologies for pregnancy diagnosis in sheep and goat: an overview. *Int J Sci Environ Technol* 2016;5:1208–1216.
 10. Rajtova V, Horak J: The effect of acute irradiation on the development of limbs in sheep. *Biologia (Bratislava)* 1976;31:171–178.
 11. Kase KR, Strom DJ, Thomadsen BR, et al: Ionizing radiation exposure of the population of the United States. Report No. 160. NCRP; 2009. [cited 2022 December 1]. Available from: www.epa.gov.
 12. Copel J, El-Sayed Y, Heine RP et al: The American college of obstetricians and gynecologists committee opinion: guidelines for diagnostic imaging during pregnancy and lactation. *Obstet Gynecol* 2017;130:e210–e216. doi: 10.1097/AOG.0000000000002355