

Ablation of endometrial cysts using endometrial biopsy forceps

Betty Radny, Tulio Prado, Jessica Klabnik-Bradford

Department of Veterinary Clinical Sciences

College of Veterinary Medicine, University of Tennessee, Knoxville, TN

Abstract

Eight mares varying in breed and age were presented for breeding soundness examination and infertility evaluation. Transrectal ultrasonographic examination of uterus revealed the presence of 1 or more endometrial cysts. Cysts were ablated by removing a portion of cyst wall using endometrial biopsy forceps. All mares became pregnant following artificial insemination performed 1 or 2 estrous cycles following ablation.

Keywords: Mare, endometrium, cyst, pregnancy, biopsy forceps

Background

Pregnancy failure can be due to stallion and management factors, failure of conception, early embryonic death, and failure of maternal recognition of pregnancy due to an endometrial cyst(s). Endometrial cysts can induce pregnancy loss by interfering with embryo mobility.^{1,2} Cysts can be ablated by surgical excision, hysteroscopic biopsy forceps, snare, laser (diode, CO₂, or Nd/YAG laser), electrocautery or by injection of 70% ethanol (ethanol sclerotherapy technique³). Most methods are expensive and can be uneconomical for many mare owners. Use of endometrial biopsy forceps as a manual ablation method has apparently not been reported. Benefits are low cost, minimal sedation, mild endometrial scarring and improved fertility.

Case presentation

History

Eight mares varying in breed and age (6 - 22 years) were examined for infertility during 2017 - 2019 breeding seasons. Mares failed to establish pregnancy despite multiple artificial inseminations with fertile stallion semen. A detailed breeding soundness examination was performed (Table 1).

Table 1. Breeding Soundness Examination Findings

#	Breed	Year examined	Age	Uterine cytology findings	Culture result	Kenney scale biopsy grade
1	Arab	2017	22	NA	NA	IIA
2	AQH	2017	17	Within Normal Limits	NA	NA
3	STB	2017	6	Within Normal Limits	No Growth	NA
4	Pony	2018	12	Within Normal Limits	NA	NA
5	Appaloosa	2018	14	NA	NA	NA
6	AQH	2018	13	Within Normal Limits	No Growth	IIB
7	AQH	2018	13	Lymphocytic endometritis	No Growth	IIB
8	STB	2019	22	NA	NA	NA

Mares had either a large single or multiple endometrial cyst(s) located in the uterine lumen ranging from 15 - 55 mm in diameter (Figure 1). Presence of endometrial cysts was suspected to be the cause of infertility in all 8 mares, possibly due to interference in embryo mobility resulting in early pregnancy loss.^{1,2}

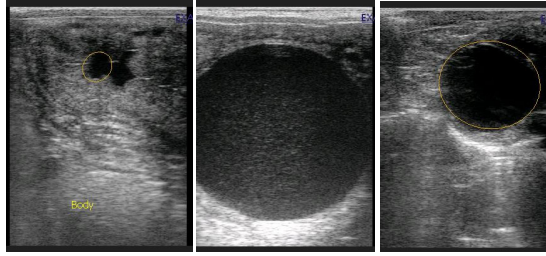


Figure 1. Examples of ultrasonographic images of endometrial cysts

Treatment

Mares were sedated with 0.4 ml of detomidine hydrochloride (Dormosedan, Zoetis Inc., Kalamazoo, MI) given intravenously. Location of cyst(s) within the uterus was identified by transrectal ultrasonographic examination. Tail was bandaged with rolled gauze, elevated, and secured to the dorsal cross-bar of the stock. Feces were removed manually from the rectum and the perineum scrubbed with povidone-iodine soap and rinsed with water. A 30-cm long endometrial biopsy forceps (Equine Alligator Forceps, Meditools.com.au) was inserted into vagina and cervix was dilated digitally to introduce forceps into uterine lumen. Cyst was stabilized transrectally between index and middle finger, as the forceps were pressed against the cyst. A 5-mm portion of cyst wall (Figure 2) was removed. If multiple cysts were present, procedure was repeated until a small portion of each cyst was removed. Transrectal ultrasonography confirmed complete deflation of cyst(s).

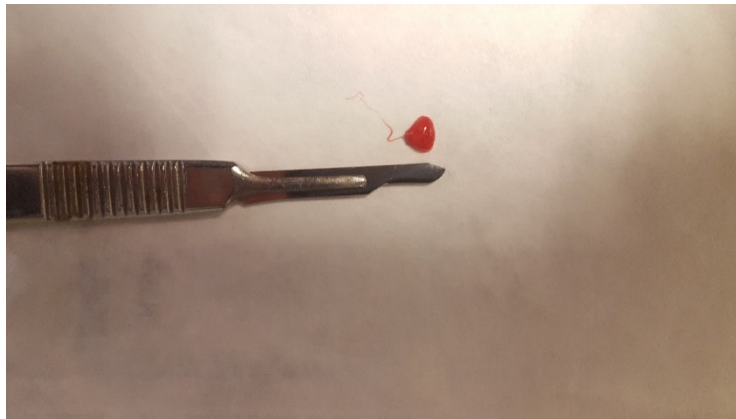


Figure 2. Portion of a wall of a cyst removed by endometrial biopsy forceps

After cyst ablation, the uterus was infused with 2 g of ampicillin (Ampicillin Sodium, G.C. Hanford Manufacturing Co., Syracuse, NY). Ovulation was induced in mares that were in estrus at the time of cyst ablation with 1.8 mg deslorelin acetate given intramuscularly (SucroMate™, Thorn BioScience LLC, Louisville, KY) when the follicle reached > 35 mm, as determined by transrectal ultrasonographic examination. Mares were bred with chilled semen either at 24 hours after ovulation induction or at next estrus (Table 2).

Mares (regardless of estrous cycle stage) were treated with 20 units of oxytocin (Bimeda MTC Animal Health Inc. Cambridge, ON, Canada) 4 - 6 hours after post-ablation ampicillin treatment. Mares in estrus during ablation were given a second oxytocin treatment 8 hours following insemination with chilled semen, to prevent fluid accumulation in uterus.

Table 2: Endometrial cysts' sizes, breeding information, and ablation outcomes

#	Breed	Year examined	Estrous cycle stage ¹	Endometrial cysts size in mm	Interval between ablation and breeding	MROP ²
1	Arab	2017	Estrus	20	22 days	Yes
2	AQH	2017	Estrus	16	22 days	Yes
3	STB	2017	Diestrus	55	1 year later	Yes
4	Pony	2018	Estrus	15	5 days	Yes
5	Appaloosa	2018	Estrus	20	1 day	Yes
6	AQH	2018	Estrus	26, 16	2 days	Yes
7	AQH	2018	Estrus	18	40 days ³	Yes
8	STB	2019	Estrus	30 x 3	1 day	Yes

¹Stage of estrous cycle (based on transrectal ultrasonographic examination of ovaries) at ablation

²Designates if mare became pregnant and carried embryo past maternal recognition of pregnancy (MROP)

³Mare #7 failed to ovulate at first post-ablation estrus (~ 20 days after ablation)

Three mares were bred at first estrus following ablation, became pregnant and maintained pregnancy past maternal recognition of pregnancy (MROP). Four mares were bred at concurrent estrus following ablation and were able to maintain pregnancy past MROP. One mare had the largest cyst (Figure 3) that completely blocked the left uterine horn. This mare was in diestrus with no signs of edema, making it difficult to dilate cervix. Cervix was dilated by applying 400 µg of misoprostol (Greenstone LLC, Peapack, NJ). Misoprostol was crushed and mixed in sterile lubricant and applied to cervix. Cervix was digitally dilated over 2 - 3 hours after misoprostol application. Following cyst ablation, transrectal ultrasonographic examination was performed to confirm ablation (Figure 4). Mare was bred artificially at the following season after confirming cyst absence (Figure 5) and became pregnant.

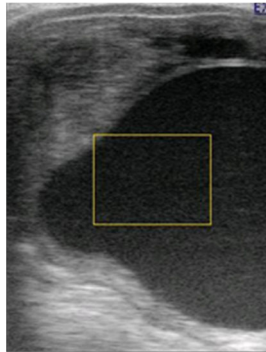

Figure 3. Ultrasonogram of left uterine horn of a mare; note the 55-mm cyst that completely blocked the lumen

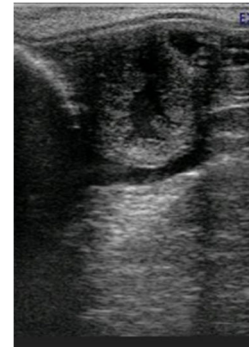

Figure 4. Ultrasonogram of left uterine horn of a mare following cyst ablation

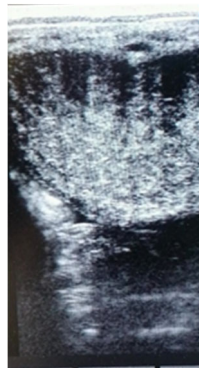

Figure 5. Ultrasonogram of left uterine horn of a mare 1 year after cyst ablation

Outcome

All 8 mares became pregnant, despite varying intervals between ablation and insemination.

Discussion

Endometrial cysts are often observed in mares > 10 years of age. Mares with 1 or more cysts of < 2 - 5 mm in diameter can become pregnant; however, 1 large or multiple small cysts may interfere with embryo mobility, a critical component of maternal recognition of pregnancy (MROP).^{4,5} Cysts located at the base of uterine horns may be especially problematic.⁶ An endometrial cyst may mimic an embryonic vesicle during ultrasonographic or transrectal examination of uterus.^{4,7} Uterine mapping prior to breeding is often included in the medical record to help distinguish between embryo and cyst. Endometrial cysts typically arise from lymphatic lacunae⁸⁻¹¹ and can range from microscopic to centimeters in diameter. As the cyst increases in size, it protrudes further into the uterine lumen and is more likely to interfere with MROP.¹ Regardless of mare's age, if embryo attaches adjacent to an endometrial cyst, the cyst can act as a space occupying mass, altering embryonic vesicle configuration. This may interfere with development of embryonic vesicle and may lead to embryo loss. An embryo that attaches directly adjacent to an endometrial cyst may suffer deprivation of nutrients, leading to its death.¹¹

Cyst can be excised surgically or ablated transendoscopically using endoscopic biopsy forceps or snare, a laser (diode, CO₂, or Nd/YAG laser) or by electrocautery.¹¹⁻¹³ However, cyst removal with these techniques can be financially difficult for some owners. Endometrial biopsy forceps introduced blindly into uterus allows clinician to perform transrectal ablation of cyst in field conditions. This process is financially more feasible than traditional techniques. Removing a section of each cyst wall has prevented cyst from refilling and is assumed to create minimal scarring. It is possible that there may be less endometrial scarring, facilitating embryo attachment. Given the simple and quick operation of the procedure, endometrial cyst ablation with endometrial biopsy forceps followed by transrectal ultrasonographic conformation is feasible both in hospital and ambulatory settings.

Learning points

- Endometrial cysts can be mistaken for an embryo during pregnancy diagnosis.
- Endometrial cysts can interfere with mobility of embryo and cause its death.
- Endometrial cysts can be ablated with endometrial biopsy forceps.

References

1. Ginther OJ, Pierson RA: Ultrasonic anatomy and pathology of the equine uterus. *Theriogenology* 1984;21:505-516.
2. Brook D, Frankel K: Electrocoagulative removal of endometrial cysts in the mare. *Equine Vet Sci* 1987;7:77-81.
3. Carluccio A, Gloria A, Mariotti F, et al: Ethanol sclerotherapy for the treatment of uterine cysts in the mare. *J Equine Vet Sci* 2018;63:27-29.
4. Stout TAE: The early pregnancy. In: *Breeding Management and Artificial Insemination*. 2nd edition. St. Louis: Elsevier Saunders; 2009. p. 223-239.
5. Eilts BE, Scholl DT, Paccamonti DL, et al: Prevalence of endometrial cysts and their effect on fertility. *Biol Reprod* 1995;5:527-532.
6. Pycock JF: Breeding management of the problem mare. In: *Breeding Management and Artificial Insemination*. 2nd edition. St. Louis: Elsevier Saunders; 2009. p. 141-142.
7. LeBlanc MM, Lopate C, Knottenbelt DC, et al: The mare. In: *Equine Stud Farm Medicine and Surgery*. 1st edition. London: Elsevier Saunders; 2003. p. 203-204.
8. Ferreira JC, Gastal EL, Ginther OJ: Uterine blood flow and perfusion in mares with uterine cysts: effect of the size of the cystic area and age. *Reproduction* 2008;135:541-550.
9. Stanton MB, Steiner JV, Pugh DG: Endometrial cysts in the mare. *J Equine Vet Sci* 2004;24:14-19.
10. Tannus RJ, Thun R: Influence of endometrial cysts on conception rate of mares. *J Vet Med Assoc* 1995;42:275-283.
11. Brisko SP, Blanchard TL, Varner DD, et al: Pregnancy loss. In: *Manual of Equine Reproduction*. 3rd edition. Maryland Heights: Elsevier Mosby; 2011. p. 94-113.
12. Pinto C, Frazer GS: Reproduction. In: *Equine Medicine, Surgery and Reproduction*. 2nd edition, Philadelphia: Elsevier Saunders; 2013. p. 290.
13. Ley WB, Higbee RG, Holyoak GR: Laser ablation of endometrial and lymphatic cysts. *Clin Tech Equine Pract* 2002;1:28-31.