

Female pseudohermaphroditism in a Dorset sheep: a case report

Bret R. McNabb,^a Alan J. Conley,^a N. James Maclachlan^b

^aDepartment of Population Health and Reproduction and ^bDepartment of Pathology, Microbiology and Immunology, School of Veterinary Medicine, University of California- Davis, Davis, CA

Summary

A four-month old Dorset lamb was presented to the University of California-Davis (UCD) Veterinary Medical Teaching Hospital (VMTH) for correction of an inguinal hernia and castration. On physical examination, testicles were not found in the scrotum and it was presumed to be a cryptorchid ram with an inguinal hernia. Surgical exploration of the abdomen identified an intact uterus, cervix, vagina and bilateral ovaries. The urethra exited the bladder via a functional fibroelastic penis. The lamb was slaughtered at 11 months of age and the reproductive tract was harvested. The lamb had a 54-XX genotype and the gonads were histopathologically confirmed to be ovaries. A fully intact female internal reproductive tract, in conjunction with functional male external genitalia, identified this lamb as a female pseudohermaphrodite. In livestock, freemartinism and male pseudohermaphrodites are more commonly reported, whereas female pseudohermaphroditism is rare. In this case report we describe the first documented case of female pseudohermaphroditism in sheep.

Keywords: Female pseudohermaphrodite, intersex, sheep, sexual differentiation

Background

Intersexuality, or abnormal sexual development, is relatively uncommon in livestock, although it has been repeatedly documented in all species. Intersexuality is discordance between or among at least two of the three levels of sexual differentiation, specifically: genetic (at the chromosomal level, ie XX and XY), gonadal (presence of testis or ovaries) and somatic (associated with development of the internal genital tract or external genitalia). The presence of both ovarian and testicular tissue within the gonads results in a true hermaphrodite, with varying phenotypic expressions. This may result from mosaicism or chimerism, in which multiple cell chromosomal populations exist within one individual that are derived from the same or different zygotes, respectively. Where the lack of concordance is between the gonadal sex and the form of the internal or external genitalia, the condition is referred to as pseudohermaphroditism. The most common cause of female pseudohermaphroditism (ovaries accompanied by masculinization of the internal ducts, with either retention of the mesonephric or regression of the paramesonephric ducts, and/or virilization of the external genitalia) in livestock species is freemartinism in cattle, wherein heterosexual twins/triplets become XX/XY blood chimeras and display a variety of phenotypes often accompanied by gonadal dysplasia. In contrast, freemartinism is far less common in sheep and other species.¹ Although male pseudohermaphroditism has been reported in many species, including sheep,² we are unaware of documented instances of female pseudohermaphroditism that do not result from freemartinism. In this report we describe a case of female pseudohermaphroditism in sheep.

Case presentation

A four-month old 22.7 kg Dorset lamb thought by the owner to be a male was presented to the UCD VMTH for evaluation and surgical correction of an inguinal hernia and castration. The lamb was twin to a ewe lamb and clinically healthy, though noticeably smaller than male flock cohorts. The physical appearance was overtly male with a prepuce positioned normally and opening ventrally. The scrotum was relatively small and the animal had teats that appeared larger than expected for a ram. No testicles were palpable but there was evidence of herniation into the right scrotal compartment. Ultrasound examination identified loops of intestine in the scrotum without obvious testicles or epididymi.

The sheep was anesthetized and surgical exploration initially involved the removal of the distal third of the scrotal skin in a customary approach for castration. The hernia sac was unremarkable however no testicles or epididymi were found in the scrotum. The sac was briefly explored and its contents appeared to be unremarkable loops of bowel. Scrotal ablation was performed in a routine manner. A second incision was made parallel to the right inguinal ring in an attempt to locate testis, but no male reproductive structures were found. However, an intact uterus and bilateral ovaries were identified amongst the herniated loops of bowel that had been within the scrotum. The loops of bowel and reproductive organs were replaced into the abdomen and the inguinal rings and external layers were closed surgically.

The lamb remained below the average body weight of its flockmates over the next three months, but was apparently attractive to the ram lambs during which time swelling developed in the perineal area. A blood sample was drawn and serum testosterone concentration was determined to be 54 pg/ml. This was considered to be inconsistent with the presence of functional testicular tissue.³

Treatment and outcome

The lamb was slaughtered at 11 months of age, providing an opportunity to examine the reproductive organs. The lamb's physical appearance had not significantly changed since surgical exploration of the abdomen, but the perineal swelling had continued to increase in size (Figures 1 and 2). A fully intact, grossly normal bicornuate uterus was present in the abdomen. Two ovaries with evidence of follicular development were positioned in the abdomen as would be expected for a normal female. Distal to the uterine body and cervix was a blind vagina distended with mucoid fluid. Adjacent to the distal end of the vagina was a bi-lobed, amorphous mass resembling paired seminal vesicles, one of which contained purulent exudate. The urinary bladder communicated with the urethra, which ran through a juvenile penis still attached distally to the preputial mucosa (Figure 3).

Histopathology confirmed the presence of bilateral ovaries with active folliculogenesis on each gonad. Primary and secondary follicles with unremarkable oocytes were present, as well as a discrete corpus luteum indicative of recent ovulation. While follicular development was ongoing, the ovary itself was hypoplastic and disorganized with a paucity of follicles. There was no evidence of testicular tissue within either ovary. The uterus was histologically unremarkable in both horns.

The mass adjacent to the vagina contained glandular tissue resembling an undifferentiated accessory sex gland. The secretory glandular epithelium was transitional with prominent squamous metaplasia. These metaplastic changes are consistent with estrogenic stimulation seen in other species.⁴

Genotyping from a preserved muscle biopsy was performed by the UCD Veterinary Genetics Laboratory. Following fibroblast amplification, genotyping for amelogenin only showed presence of the X-variant, indicating this animal was chromosomally XX. Polymorphic genetic markers typically used for parentage analysis found no evidence of chimerism.

Discussion

Normal sexual differentiation in mammals is directed by the sex chromosome constitution (XX, XY, or variations thereof). Specifically, the SRY-region of the Y chromosome drives normal testicular development in utero. Clinically, the sex (female or male) is defined by the presence of ovaries or testis. The stabilization and development of the mesonephric (Wolffian) ducts, and concomitant regression of the paramesonephric (Mullerian) ducts, is induced by testicular testosterone and anti-Mullerian hormone (AMH), respectively, synthesized and secreted by the testes if the fetus is male. The external genitalia and accessory sex glands are also induced to develop from embryonic primordia by dihydrotestosterone (DHT) synthesized locally within these tissues from circulating testosterone. The ovaries of female fetuses are relatively inactive endocrinologically and in the absence of testosterone and AMH the mesonephric ducts regress and the paramesonephric ducts develop into oviducts, uterus and anterior vagina. Similarly, in the absence of testosterone and DHT, the genital tubercle remains undeveloped and genital folds develop into the lips of the vulva. The fetus in question was a female pseudohermaphrodite with extensive virilization of the external genitalia suggestive of androgen exposure in utero.

Freemartinism is the most common cause of female pseudohermaphroditism in livestock but is an unlikely explanation in this case. Freemartinism is common and well-documented in cattle, less so in sheep, and is thought to be more common in breeds with high ovulation rates and multiple lambs.⁵ In each case, it is associated with placental anastomosis between multiple fetuses that results in blood chimerism. When placental anastomosis involves fetuses of different genetic sex, development of the female fetus is thought to be disrupted by the testosterone and AMH circulating from the male co-twin. Exposure of testosterone and AMH from the male to the female results in varying degrees of gonadal and phenotypic dysgenesis, and subsequent subfertility and infertility of each offspring. The formation of blood chimeras (XX/XY) is the basis for confirmatory karyotype testing.¹ The female in question is unlikely to be a freemartin because she was not co-twin to a male, but rather to a fertile female sibling that later became pregnant and lambled uneventfully. The likelihood of a third male fetus that developed long enough to have undergone sexual differentiation but subsequently died without leaving any evidence of its existence in utero seems remote.

True hermaphroditism must be considered in cases like this, and has been reported in sheep with either bilateral ovotestis^{6,7} or one testicle and one ovary.⁸ These cases were phenotypically female with a female reproductive tract, and confirmed with histopathology of the gonads to have both ovarian and testicular tissue. We have eliminated this possibility with histopathology. Male pseudohermaphroditism (testis with female genitalia) has been reported in the sheep^{2,9} and may result from decreased androgen production or androgen insensitivity in target tissues. The higher incidence of these cases is reasonable, in that without testosterone, AMH and dihydrotestosterone the female tract is by many accounts the default pathway for development. The opposite is quite unusual.

Female pseudohermaphroditism is extremely rare but has been reported in cattle,^{10,11} dogs,¹² humans,¹³⁻¹⁵ and bears, including polar bears.¹⁶ These phenotypes range from slight clitoral hypertrophy and infertility to fully-developed external male genitalia. While some cases resulted from mosaicism (SRY-positive and not), others had only XX chromosomal compositions, suggesting extra-gonadal hormonal influences. Investigation into polar bears in Norway with a relatively high incidence of female pseudohermaphroditism suggested exposure to chemical environmental pollutants, specifically polychlorinated biphenyls (PBCs), which may disturb the differentiation of organs with gonadal hormone receptors.¹⁶ In any instance, there is a finite window during gestation and sexual differentiation when exposures to such factors must occur to have such severe effects on normal fetal development.

The etiology of pseudohermaphroditism in this ewe remains unknown, but it is consistent with the effect of exposure to androgens during days 30-60 of gestation which induces a similar degree of virilization in ewe lambs experimentally exposed to testosterone.^{17,18} The lack of any abnormality in the female co-twin argues strongly that the androgen presumed to induce genital masculinization of affected ewe lamb must have been synthesized by the lamb itself, even if not gonadal. Exogenous androgen exposure during a very limited developmental window is plausible when all offspring are affected, but not when affected offspring are accompanied by normal siblings as in this case. In humans, female pseudohermaphroditism is a common sequel to congenital adrenal hyperplasia,^{13,15,19} an autosomal recessive disorder. Female fetuses with a deficiency in the enzymatic pathway necessary for cortisol synthesis (most frequently due to lack of 21-hydroxylase) have increased ACTH levels due to lack of feedback, leading to over-stimulation of the adrenal zona reticularis and overproduction of adrenal androgens.²⁰ Male genitalia will develop despite an XX-karyotype, though these individuals often have concurrent electrolyte imbalances because of adrenal dysfunction. Other than humans, this condition has been reported to occur only twice, both instances in domestic cats.^{21,22} Enlargement of the adrenal glands of the affected ewe were not noted at slaughter, nor were there any other symptoms suggestive of adrenocortical deficiency, but no other possible cause seems plausible to the authors based on what is known.

Sex reversal, as occurs when the genetic sex and gonadal sex are divergent, was excluded based on genetic analysis and gonadal histopathology.

While there must have been unusual androgen exposure to this developing lamb, endogenous estrogen and progesterone must have concurrently been secreted. This sheep had bilateral ovaries, a fully

intact female reproductive tract and functional external male genitalia. While adrenal glands were not assessed postmortem, they remain a plausible source for the male phenotype seen here. The undifferentiated accessory sex gland present must have developed under the presence of testosterone and subsequent conversion to DHT, and the apparent effect of estrogen on the glandular tissue is to be expected with functional ovaries. Similar effects, including epithelial hyperplasia and squamous metaplasia, are seen in the prostates of dogs with estrogen exposure²³ that often results from estrogen-secreting tumors.

It is difficult to adequately explain the unusual presentation of this sheep. The chromosomal sex matches the functional ovarian tissue, however the androgens inducing penile and scrotal development cannot be readily explained. There is no known androgen or chemical exposure in utero, as the female twin to this sheep was bred and maintained a normal pregnancy. The presence of the SRY-gene is unlikely in this case, as is underlying gonadal mosaicism, though these cannot be entirely ruled out in this case and thus the true cause in this sheep therefore remains unknown. Female pseudohermaphroditism is a rare occurrence in domestic species but should be considered when sexual ambiguity is present.

Learning points

- Sexual differentiation in mammalian species is complex, with the potential for error at any stage.
- Female pseudohermaphroditism is rare in domestic animals, and the underlying cause may remain ambiguous some cases.
- All levels of intersexuality should be considered when sexual ambiguity is present.

Acknowledgements

Joan Palmero DVM, Lee V. Millon, Dana Van Liew

References

1. Padula AM: The freemartin syndrome: an update. *Anim Reprod Sci* 2005;87:93-109.
2. Bruere AN, McDonald MF, Marshall RB: Cytogenetical analysis of an ovine male pseudohermaphrodite and the possible role of the Y chromosome in cryptorchidism of sheep. *Cytogenetics* 1969;8:148-157.
3. Falvo RE, Buhl AE, Reimers TJ, et al: Diurnal fluctuations of testosterone and LH in the ram: effect of HCG and gonadotrophin-releasing hormone. *J Reprod Fertil* 1975;42:503-510.
4. Barrack ER, Berry SJ: DNA synthesis in the canine prostate: effects of androgen and estrogen treatment. *Prostate* 1987;10:45-56.
5. Parkinson TJ, Smith KC, Long SE, et al: Inter-relationships among gonadotrophins, reproductive steroids and inhibin in freemartin ewes. *Reproduction* 2001;122:397-409.
6. Bunch TD, Callan RJ, Maciulis A, et al: True hermaphroditism in a wild sheep: A clinical report. *Theriogenology* 1991;36:185-190.
7. Fayrer-Hosken RA, Huber TL, Miller DM, et al: Infertility in a ewe as a result of ovotestis. *J Am Vet Med Assoc* 1992;200:1528-1529.
8. Smith KC, Long SE, Parkinson TJ: A case of true hermaphroditism in a sheep. *Vet Rec* 1996;138:497-498.
9. Bruere AN, Macnab J: A cytogenetical investigation of six intersex sheep, shown to be freemartins. *Res Vet Sci* 1968;9:170-180.
10. Burton MJ, Momont HW: Pseudohermaphroditism in a Holstein heifer. *Vet Rec* 1986;119:155-156.
11. Takagi M, Yamagishi N, Oboshi K, et al: A female pseudohermaphrodite Holstein heifer with gonadal mosaicism. *Theriogenology* 2005;63:60-71.
12. Weaver AD, Harvey MJ, Munro CD, et al: Phenotypic intersex (female pseudohermaphroditism) in a dachshund dog. *Vet Rec* 1979;105:230-232.
13. Jorge JC, Echeverri C, Medina Y, et al: Male gender identity in an XX individual with congenital adrenal hyperplasia. *J Sex Med* 2008;5:122-131.
14. Rajender S, Rajani V, Gupta NJ, et al: SRY-negative 46,XX male with normal genitals, complete masculinization and infertility. *Mol Hum Reprod* 2006;12:341-346.
15. Marino TA: Embryology and disorders of sexual development. *Perspect Biol Med* 2010;53:481-490.
16. Wiig O, Derocher AE, Cronin MM, et al: Female pseudohermaphrodite polar bears at Svalbard. *J Wildl Dis* 1998;34:792-796.
17. Clarke IJ, Scaramuzzi RJ, Short RV: Effects of testosterone implants in pregnant ewes on their female offspring. *J Embryol Exp Morphol* 1976;36:87-99.

18. Roselli CE, Estill CT, Stadelman HL, et al: Separate critical periods exist for testosterone-induced differentiation of the brain and genitals in sheep. *Endocrinology* 2011;152:2409-2415.
19. Kirli EA, Karnak I, Ciftci AO, et al. An unexpected diagnosis in children with male phenotype and bilateral nonpalpable gonad: congenital adrenal hyperplasia with female genotype. *Pediatr Surg Int* 2013.
20. Hanley NA, Arlt W. The human fetal adrenal cortex and the window of sexual differentiation. *Trends Endocrinol Metab* 2006;17:391-397.
21. Knighton EL. Congenital adrenal hyperplasia secondary to 11beta-hydroxylase deficiency in a domestic cat. *J Am Vet Med Assoc* 2004;225:238-241, 231.
22. Owens SL, Downey ME, Pressler BM, et al. Congenital adrenal hyperplasia associated with mutation in an 11beta-hydroxylase-like gene in a cat. *J Vet Intern Med* 2012;26:1221-1226.
23. Mahapokai W, van den Ingh TS, van Mil F, et al. Immune response in hormonally-induced prostatic hyperplasia in the dog. *Vet Immunol Immunopathol* 2001;78:297-303.



Figure 1. Ante-mortem picture of a female pseudohermaphrodite sheep. Note the significant perineal swelling and lack of a vulva. This sheep has a prepuce and a functional penis.

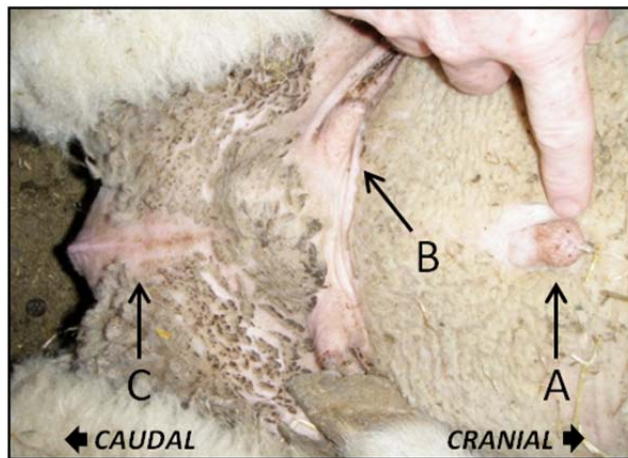


Figure 2. Sheep in a flipped position. Note the prepuce (A), enlarged teats (B) and perineal swelling (C). There appears to be a remnant where the vagina would have had an exterior opening.

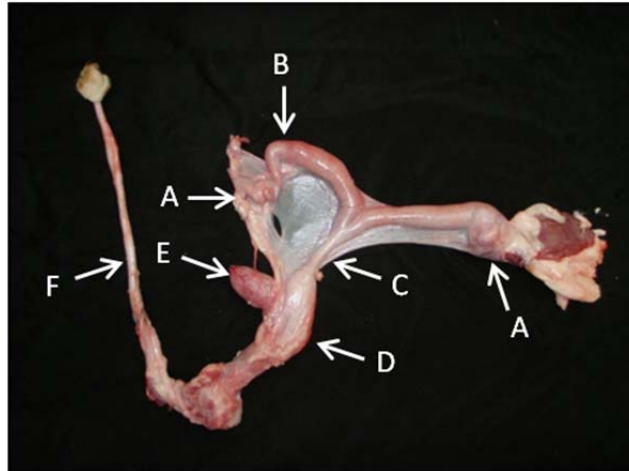


Figure 3. Gross image of the entire reproductive tract of a sexually ambiguous sheep. Note the bilateral ovaries (A), intact uterus (B), cervix (C), vagina (D), urinary bladder (E) and fibroelastic penis (F).

(Editor's note: The photographs in this paper are available in color in the online edition of Clinical Theriogenology.)