

A unique phenotypical presentation of a male pseudohermaphrodite in a dairy bull calf

Randall Bond,^a Christopher Premanandan^b

^aDepartment of Veterinary Preventative Medicine, ^bDepartment of Veterinary Biosciences, College of Veterinary Medicine, The Ohio State University, Columbus OH

Summary

A six month old Brown Swiss bull calf was referred for surgical correction of a scrotal hernia. Palpation and ultrasonography of the scrotum revealed a freely movable luminal structure in the right side of the scrotum and one descended testicle in the left portion of the scrotum. The clinical management plan included surgical correction of the small intestinal inguinal herniation followed by bilateral castration. The calf was anesthetized and taken to surgery. While performing the surgical procedure, it was discovered that intestines were not the structures involved in the hernia but rather were structures of the Müllerian duct system; the cervix and uterine horns were found within the scrotum. Additionally, the right testicle was attached to the right uterine horn and retained within the right inguinal canal. The uterus, cervix, and bilateral testes were ligated and surgically removed. The inguinal ring was surgically closed in order prevent further herniation. The calf recovered without complications and was returned to the owner.

Background

Indirect congenital inguinal herniation involving intestinal structures has been repeatedly reported in calves¹ and is by far the most common finding and the primary differential. The classification of indirect versus direct herniation is based on whether the abdominal viscera exits the abdomen through a normal body opening. Left sided herniation occurs most commonly.² The weight of the rumen is thought to predispose to left sided inguinal herniation. Bulls which have undergone significant weight loss with large inguinal rings are more predisposed to inguinal herniation. The depletion of the inguinal fat pad occurs with weight loss allowing for structures, such as intestines, to herniate through the inguinal ring into the scrotum. The findings in this case, albeit very uncommon, point to the need to include structures of the Müllerian duct system, vestigial or developed, in the differential diagnosis of structures which can herniate through the inguinal ring. Hence, in cases of male pseudohermaphroditism it must always be a consideration when evaluating an indirect inguinal hernia in a bull calf.

Case presentation

A six month old Brown Swiss bull calf was referred to The Ohio State University Large Animal Services (OSULAS) for evaluation and repair of an inguinal hernia and bilateral castration. The calf was initially evaluated by a fair veterinarian. During the weight and health screening, the veterinarian discovered the inguinal hernia and recommended that the hernia be surgically corrected. The calf was otherwise healthy and had been purchased from a neighboring farm.

Upon presentation to OSULAS, a physical examination was performed. Temperature, heart rate, and respiratory rate were all within normal limits. The animal weighed approximately 200 kilograms. Upon palpation of the scrotum, only the left testicle could be palpated along with a freely movable tubular structure within the scrotum on the right side. The descended (left) testicle was of normal size, shape, and firmness for a calf of this age. The other testicle (right) could not be palpated within the scrotum or the adjacent inguinal ring. The calf had a fully formed scrotum and no external female genitalia (Figure 1A). An ultrasound examination (Easi-Scan®; 5.0 MHz linear probe; BCF Technologies Ltd., Bellshill, UK) of the scrotum revealed a right testicle with multiple loops of a fluid-filled luminal structure resembling intestines. The ultrasonic image of the intestine is normally characterized by a single circular hyperechoic muscle layer surrounding hypoechoic to hyperechoic bowel contents. Multiple loops of bowel are generally seen and can vary in diameter. Movement of the bowel contents and intestinal wall is generally noted with indirect inguinal hernias. In this case, peristalsis was not observed. Ultrasonography of the descended testicle revealed homogenous echotexture of the seminiferous tubules with a hyperechoic

mediastinum testis. These findings were consistent with a normal ultrasonic image. The remainder of the physical findings were unremarkable.

Differential diagnosis

The primary diagnosis following physical and ultrasonographic examination was unilateral right sided cryptorchidism with small intestinal herniation. Less likely differentials included severe right sided testicular hypoplasia and or neoplasia, pseudohermaphroditism, and true hermaphroditism.

Treatment

An intravenous catheter was placed in the right jugular vein and the patient was given 6.6mg/kg ketamine (Ketaset®, Zoetis Inc., Florham Park, NJ) intravenously and 0.22mg/kg xylazine (AnaSed®, Akorn Inc., Decatur, IL) intramuscularly. The patient was then intubated and general anesthesia was maintained with sevoflurane (SevoFlo®, Abbott Laboratories, North Chicago, IL) for the remainder of the surgery. The patient was placed in dorsal recumbency and the surgical site was prepared for sterile surgery in a routine fashion. Lactated Ringer's solution (Lactated Ringer's Injection USP, Baxter Healthcare Corporation, Deerfield, IL) was administered intravenously at a maintenance rate (2.5ml/kg/hr) for the duration of the surgery. A single 8 cm incision was made through the skin and subcutaneous tissues above the right inguinal ring. The testicle within the scrotum was identified and exteriorized through this incision. There was no attachment of the testis to the visceral vaginal tunic of the scrotum. The tubular structure that was thought to be intestine was firmly attached to the left testicle. This structure was then traced to the opening of the right inguinal canal. As this was done, the right testicle which was attached to the other end of the tubular structure but still within the abdomen, was pulled through the inguinal ring. A fully formed uterus, cervix, and bilateral testes (located in position of normal ovaries) were identified (Figure 1B). The structure was then palpated intra-abdominally and appeared to have originated near the pelvic inlet. The uterine horns, cervix, and testes were then ligated with size three chromic gut (Chromic Gut, Ethicon, Cincinnati, OH) and excised near the inguinal ring. The inguinal ring, subcutaneous tissue, and skin were closed in routine fashion using size one polyglactin 910 (Vicryl®, Ethicon, Cincinnati, OH) for closure of the inguinal ring and subcutaneous tissues, and size one synthetic suture material (Braunamid®, Aesculap, Center Valley, PA) for closure of the skin. Recovery was uneventful. The patient received 500 mg flunixin meglumine intravenously (Prevail™, MWI, Boise, ID) during surgery and given 2,000 mg ceftiofur crystalline free acid (Excede®, Zoetis Inc., Florham Park, NJ) subcutaneously in the middle third of the posterior aspect of the ear where it attaches to the head, for treatment of a mild respiratory infection associated with anesthesia, and dismissed with 1 mg/kg of meloxicam tablets (Meloxicam®, Unichem Pharmaceuticals Inc., Rochelle Park, NJ) to be given every other day, orally, for three treatments.

The surgically excised tissue was submitted to the Applied Pathology Service at the Ohio State University College of Veterinary Medicine for evaluation. Grossly, the specimen consisted of a nearly complete tubular female reproductive tract (cervix, uterine body and uterine horns) (Figure 2A). The gonadal tissue was approximately 4.5 cm x 2.5 cm x 2.5 cm. The surface capsular tissue was thick and contained prominent vasculature reminiscent of the tunica albuginea. Tubular tissue was present adjacent to the gonadal tissue. The orientation and gross appearance of this tissue resembled an epididymis (Figure 2B). The tissue was fixed in 10% neutral buffered formalin and processed in a routine manner for histopathology. Histologic examination of the uterus demonstrated normal bovine endometrium, with aglandular segments of endometrium present, which resembled caruncles (Figure 3A). A tubular structure was present in the myometrium that was lined by columnar to stratified columnar ciliated epithelium interpreted as a rudimentary ductus deferens (mesonephric duct remnants; Figure 3B). Sections of the distal tubular reproductive tract demonstrated cross sections of uterine tube, including infundibulum, isthmus and ampulla as well as cross sections of aggregated, highly coiled tubules lined by ciliated columnar epithelium interpreted as an epididymis (Figure 3C and D). Histologically, the gonadal tissue consisted of numerous structures resembling seminiferous tubules that were lined by polygonal cells interpreted as Sertoli cells. These tubules were small and separated by a polygonal to spindle cell

population, interpreted as Leydig cells (Figure 3E). A lesser population of round cells typically unattached to the tubular basement membrane were present. Immunohistochemical staining directed at GATA-4 (Santa Cruz Biotechnology, Santa Cruz, CA) was performed to identify the Sertoli cell population present and to distinguish them from potential germ cells. GATA-4 is a transcription factor expressed in multiple tissues that regulate differentiation and cell proliferation. In swine, GATA-4 protein expression is observed in Sertoli cells, Leydig cells and peritubular cells. In addition, GATA-4 may play a role in the regulation of expression of Müllerian inhibitory substance.²² The GATA-4 immunohistochemistry showed prominent nuclear staining of Sertoli cells, Leydig cells and interstitial fibroblasts; however, a sporadic population of intratubular cells with round morphology and a relatively low nuclear to cytoplasmic ratio did not exhibit GATA-4 staining (Figure 3F). This population of cells was interpreted as germ cells.

A whole blood sample was collected via venipuncture from the patient. The sample was sent to The University of California Davis Veterinary Genetics Laboratory for karyotyping. A conventional staining technique was utilized where peripheral blood lymphocytes were isolated from the whole blood sample. The lymphocytes were then cultured for several days under conditions that stimulate them to divide and then be harvested. Nuclei of the cells were treated to expose chromosomes which are then stained and photographed. The chromosomes were then examined for number and structure. The calf was determined to have a normal lymphocytic karyotype of a typical male bovid (60 XY). Additionally, DNA was also extracted from the sample and tested for sex linked traits. There was no evidence of hematopoietic chimerism found and all results were consistent of a normal male bovid.

Outcome

The owners reported that the calf recovered without complications. The calf was meant to be utilized as a show animal but was disqualified due to lack of appropriate weight gain.

Discussion

Normal mammalian sex is dependent on the completion of three major stages that are under genetic and hormonal control.³ Within any of these stages, errors can occur which significantly influence the subsequent outcome of sexual development of the individual. The first stage is the establishment of chromosomal sex (XX or XY) that occurs at fertilization. Based on the chromosomal sex, the genital ridges of the developing indifferent embryo form the sex cords, in which germ cells migrate in order to develop into testes or ovaries.⁴ Determination of gonadal differentiation is dependent on the *SRY* (sex determining region Y) gene expression of the Y chromosome as well as other factors some of which all are not fully known.⁵ If differentiation into the male gonadal phenotype takes place, production of testosterone (T) by testicular Leydig cells and anti-Müllerian hormone (AMH) by Sertoli cells results.⁶ These two products promote the differentiation of the mesonephric (Wolffian) duct into the male tubular genitalia and regression of the paramesonephric (Müllerian) ducts, respectively. In the absence of T and AMH, there is a promotion and differentiation of the paramesonephric (Müllerian) ducts and regression of the mesonephric (Wolffian) ducts to form the female gonadal phenotype. The external genitalia and accessory sex glands are also induced to develop from embryonic primordia by dihydrotestosterone (DHT) made within these tissues from circulating testosterone.⁶

Hermaphroditism and pseudohermaphroditism are examples of errors that can occur during this development. Errors that occur during this time are considered a condition of intersex. Intersex incorporates three conditions: true hermaphroditism, freemartinism, and pseudohermaphroditism. True hermaphroditism is characterized as a combination of ovaries, testes, and/or ovotestes and mosaicism may occur commonly.⁷ For example, true hermaphrodites may have a testicle on one side, and an ovary on the contralateral side. Ovotestes exhibit the presence of testicular and ovarian tissue in the same gonad. A freemartin is the most common form of intersexuality found in cattle.⁸ It occurs when the developing heterosexual twin fetuses share a vascular placental anastomosis. This connection then consequentially masculinizes the developing female reproductive tract, due primarily to the influence of anti-Müllerian hormone.⁸ Typically, the females are sterile and have absence of tubular genitalia.⁴

Finally, a pseudohermaphrodite (PH) occurs when there is a difference between the external genitalia and the true phenotypic gonadal sex of the animal.⁹ A female PH is a genetic and gonadal female with partial masculinization of the external genitalia. In food producing animals, female PH is much less common than male PH.⁹ This is because female gonadal differentiation is the default without the presence of testosterone, AMH, and dihydrotestosterone. Some cases of female PH have resulted from mosaicism, while others had XX chromosomal compositions suggesting that extra-gonadal hormonal influences played a role. In one study, a high incidence of female pseudohermaphroditism in polar bears was suggested to be due to polychlorinate biphenyls (PBCs), which may disturb the differentiation of organs.¹⁰

Conversely, a male PH has testes and female external genitalia.¹¹ Male PH can have undescended testes and varying combinations of male and female structures and they may have either XY or XX chromosomal constitution. In male PH, there may be a failure of normal production of androgens by the testicles or androgen insensitivity from the respective tissues. If either of these occur, the outcome resorts to the default, which is female, and the mesonephric system fails to develop.¹² In this case, it is speculated that there was androgen insensitivity as the testicles were histologically normal and at least one was present in the correct location. Cases of male pseudohermaphroditism have been reported in most domestic species including: dogs,³ cats,¹³ cattle,¹² pigs,¹⁴ sheep,^{15,16} horses,¹⁷ white-tailed deer,¹⁸ and captive Arabian oryx.¹⁹ The rate at which this abnormal development occurs is variable within the species.²⁰ In humans, as well as in canines, intersex conditions have been reclassified as disorders of sexual development (DSD). Disorders of sexual development classification often takes in account the genotypic abnormalities as well as phenotypic abnormalities observed clinically. Bovine intersex conditions have not been reclassified in such a manner; however, utilizing the classification for canines, this case may be referred to as 60 XY persistent Müllerian duct disorder of sexual development.²¹

This particular case demonstrates two intriguing clinical implications. The first is that a male PH can present clinically with the gonads in a scrotal location. This suggests that the condition can be a clinical differential for cryptorchidism and testicular hypoplasia/aplasia. In terms of long-term prognosis, the patient had limited reproductive and financial potential. However, it is interesting to speculate on the manner in which the gonads would have continued to develop if surgery was not performed. Since germ cells were still present in these testes as shown by the GATA-4 immunohistochemical stain, it is possible that spermatogenesis may have taken place at puberty given the intrascrotal location of at least one testis.

In conclusion, this case report describes an unusual presentation of a bovine male PH in which male gonadal tissue was present in the scrotum as well as portions of the aberrant female reproductive tract. To the authors' knowledge, this case is unique in that there have been no other published reports describing this specific type of phenotypic presentation of PH.

Learning points

- In clinical situations of presumptive inguinal herniation, male pseudohermaphrodite should be listed as a possible differential diagnosis along with cryptorchidism, testicular hypoplasia or testicular aplasia.
- Pseudohermaphroditism is a condition of intersex. It is characterized by having external genitalia that is different from the true gonadal sex of the animal.

Acknowledgement

We gratefully acknowledge Lee V. Millon and the UC Davis Veterinary Genetics Laboratory for the karyotype results presented in this manuscript.

References

1. Wolfe D, Rodning S: Diagnosis and management of inguinal hernia in bulls. In: Anderson D, Rings M, editors. Food animal practice. 5th ed. St. Louis: Saunders Elsevier; 2009. p. 356-359.
2. Turner AS, McIlwraith CW: Techniques in large animal surgery. Philadelphia: Lea and Febiger; 1989. p. 313.
3. Bigliardi E, Parma P, Peressotti P, et al: Clinical, genetic, and pathological features of male pseudohermaphroditism in dog. *Reprod Biol Endocrinol* 2011;9:1-7.

4. Ladds PW: Congenital abnormalities of the genitalia of cattle, sheep, goats, and pigs. *Vet Clin North Am Food Anim Pract* 1993;9:127-144.
5. Takagi M, Yamagishi N, Oboshi K, et al: A female pseudohermaphrodite Holstein heifer with gonadal mosaicism. *Theriogenology* 2005;63:60-71.
6. McNabb B, Conley A, Maclachlan, NJ: Female pseudohermaphroditism in a Dorset sheep: a case report. *Clin Therio* 2014;6:105-110.
7. Hadjiathanasiou CG, Brauner R, Lortat-Jacob S, et al: True hermaphroditism: genetic variants and clinical management. *J Pediatr* 1994;125:738-744.
8. Padula AM: The freemartin syndrome: an update. *Anim Reprod Sci* 2005;87:93-109.
9. Jainudeen MR, Hafez ESE: Genetics and reproductive failure. In: Hafez, ESE, editor: *Reproduction in farm animals*. 5th ed. Philadelphia: Lea and Febiger; 1987. p. 436-451.
10. Wiig O, Derocher AE, Cronin MM, et al: Female pseudohermaphrodite polar bears at Svalbard. *J Wildl Dis* 1998;34:792-796.
11. Lott D, Benirschke K, McDonald J, et al: Physical and behavioral findings in a pseudohermaphrodite American bison. *J Wildl Dis* 1993;29:360-363.
12. Moriyama C, Tani M, Nibe K, et al: Two cases of bovine male pseudohermaphrodites with different endocrinological and pathological findings. *J Vet Med Sci* 2010;72:507-510
13. Vallefucio R, Alleaume C, Jardel N, et al: Type II atresia ani associated with rectovaginal fistula in a male pseudohermaphrodite kitten. *Can Vet J* 2013;54:475-478.
14. Halina WE, Barrales DW, Partlow GD, et al: Intersexes in swine: a problem in descriptive anatomy. *Can J Comp Med* 1984;48:313-321.
15. Bruere AN, McDonald MF, Marshall RB: Cytogenetical analysis of an ovine male pseudohermaphrodite and the possible role of the Y chromosome in cryptorchidism of sheep. *Cytogenetics* 1969;8:148-157.
16. Bruere AN, Macnab J: A cytogenetical investigation of six intersex sheep, shown to be freemartins. *Res Vet Sci* 1968;9:170-180.
17. Bouters R, Vandeplassche M, Moor A: An intersex (male pseudohermaphrodite) horse with 64 XX/65 XXY mosaicism. *Equine Vet J* 1972;4:150-153.
18. Scanlon P, Urbson D, Sullivan J: A male pseudohermaphrodite white-tailed deer resembling an antlered doe. *J Wildl Dis* 1975;11:237-240.
19. Padilla L, Dutton C, Bauman J, et al: XY male pseudohermaphroditism in a captive Arabian oryx (*Oryx leucoryx*). *J Zoo Wildl Med* 2005;36:498-503.
20. Payan-Carreira R, Pires M, Quaresma M, et al: A complex intersex condition in a Holstein calf. *Anim Reprod Sci* 2008;103:154-163.
21. Poth T, Breuer W, Walter B, et al: Disorders of sex development in the dog-adoption of a new nomenclature and reclassification of reported cases. *Anim Reprod Sci* 2010;121:197-207.
22. LaVoie HA. The role of GATA in mammalian reproduction. *Exp Biol Med* 2003;228:1282-1290.

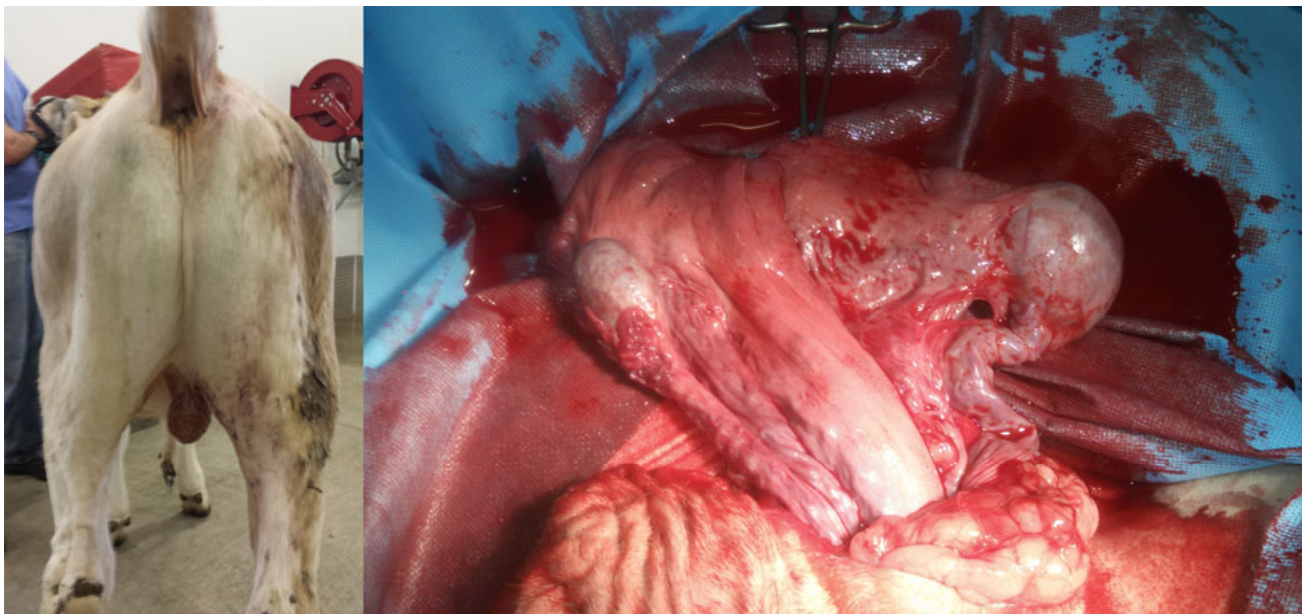


Figure 1. Left: View of the caudal aspect of the calf showing a fully formed scrotum and no external female genitalia. Right: Surgical image of the uterus, cervix, uterine horns, and bilateral testes originating through the right inguinal canal.

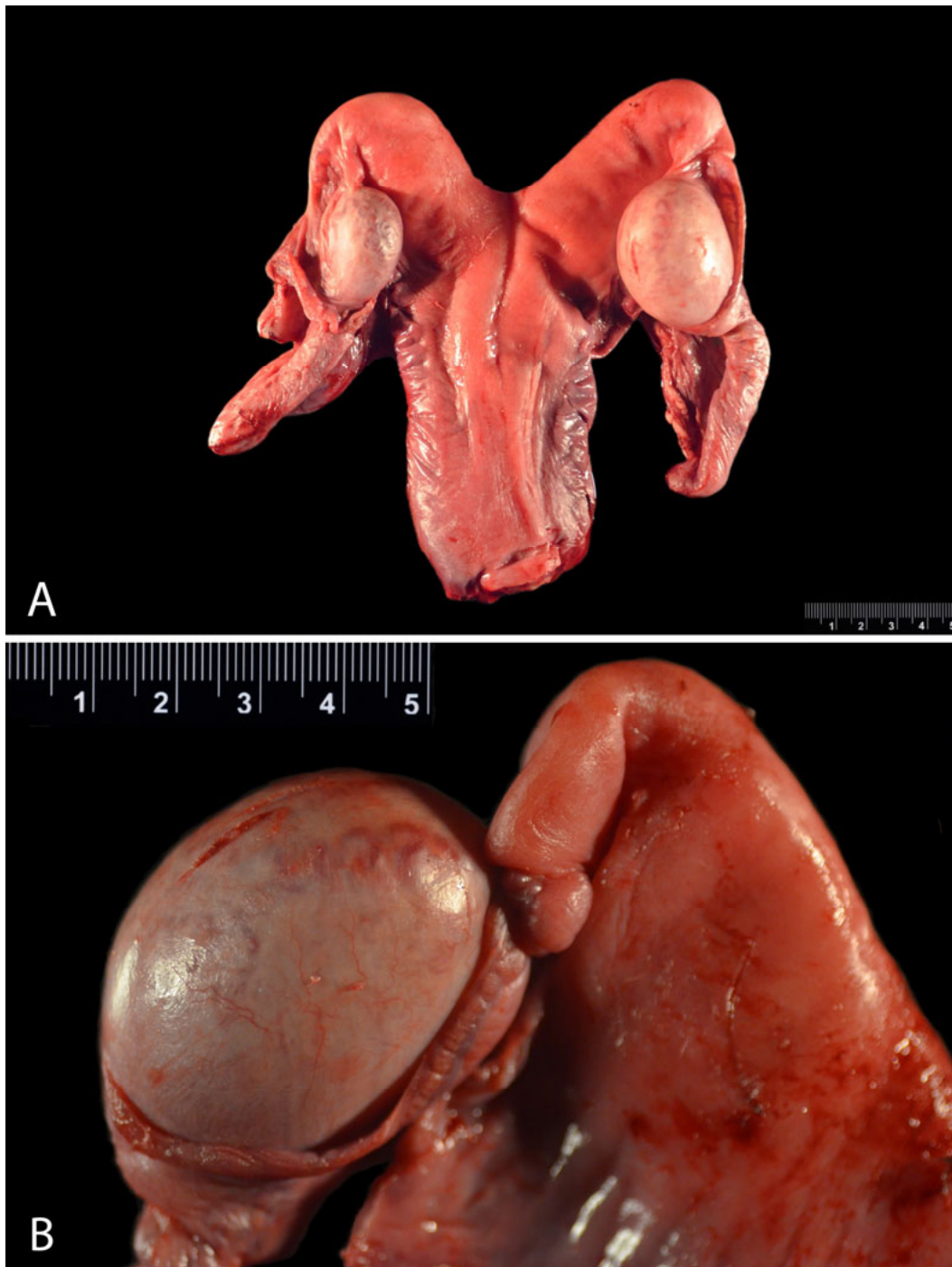


Figure 2. Gross images of the surgically excised reproductive tract. A. The entire tubular female reproductive tract is demonstrated in this image in addition to gonads at the distal aspect of each uterine horn. B. Gonadal tissue present at the distal aspect of the right uterine horn. Note the tubular structure resembling epididymis adjacent to the gonad and the prominent vasculature associated with the tunica albuginea typical of the external surface of the testicle.

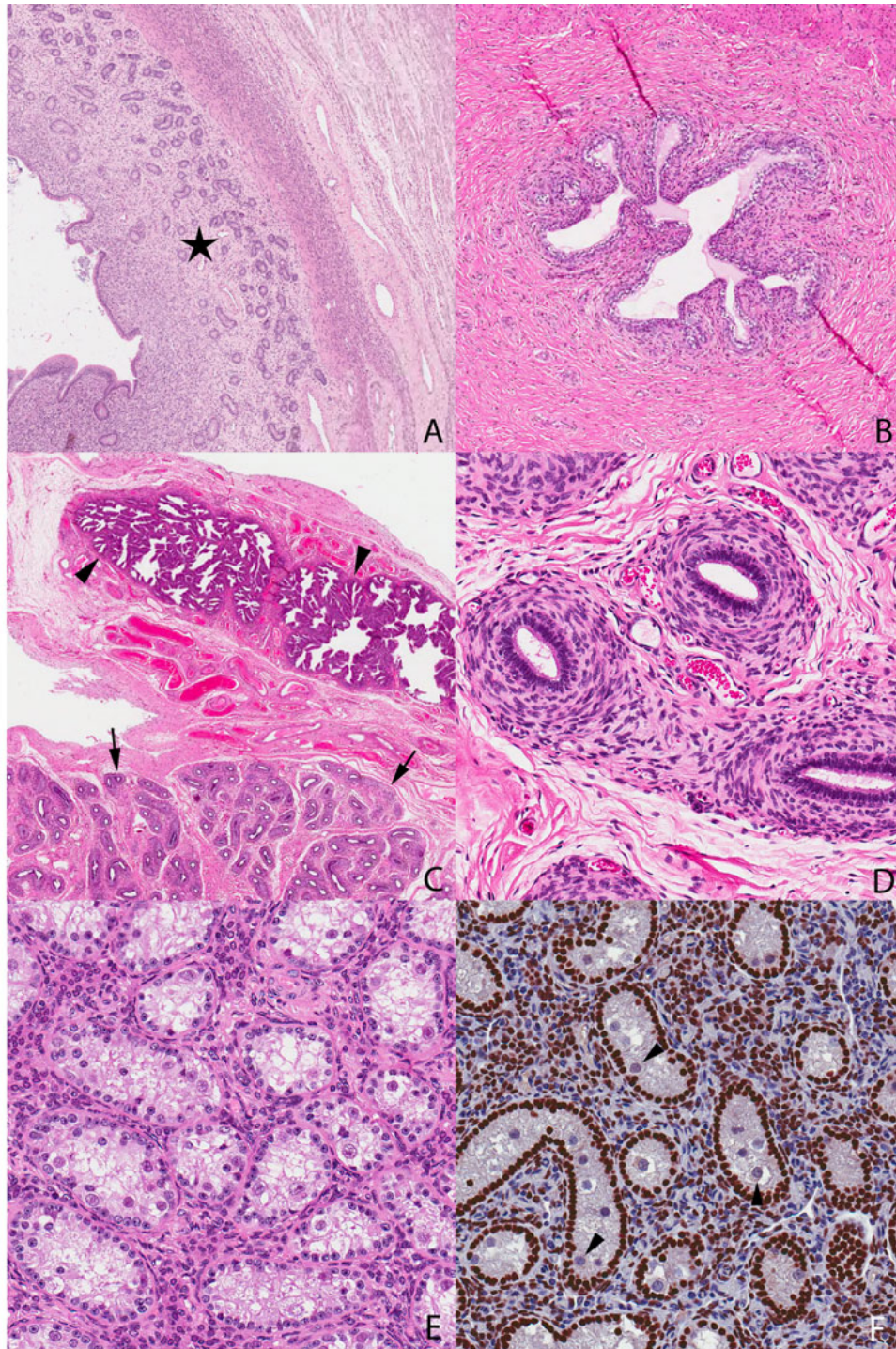


Figure 3. A. Photomicrograph demonstrating endometrium and myometrium from the tubular reproductive tract. B. Photomicrograph of a tubular structure present in the myometrium interpreted as mesonephric duct remnant. C. Multiple cross sections of tissue resembling infundibulum of the uterine tube (arrowheads) and epididymal tubules (arrows). D. Multiple cross sections of epididymal tubules at higher magnification. E. Photomicrograph of gonadal parenchyma containing seminiferous tubules lined by Sertoli cells. Note the round cells present in the lumen of several tubules that were interpreted as germ cells. F. Photomicrograph of GATA-4 immunohistochemical stain of gonadal parenchyma. Note the strong positive nuclear staining of Sertoli cells and the absence of nuclear staining of gonocytes (arrowheads).

(Editor's note: The photographs in this manuscript are available in color in the online edition of *Clinical Theriogenology*.)