

Modified diff-quick staining for canine sperm morphology

Mariana Mazzuchini,^a Guilherme Novello,^a Lorenzo Segabinazzi^b

^aDepartment of Veterinary Surgery and Animal Reproduction, School of Veterinary Medicine and Animal Science, São Paulo State University, Botucatu, Brazil

^bRoss University School of Veterinary Medicine, Basseterre, St. Kitts, West Indies

Abstract

Sperm morphology assessment requires specialized microscopes or stains. Diff-quick (DQ) is considered a universal stain that is cost-effective; however, morphological evaluation of sperm using DQ staining is poor and not encouraging. Therefore, this study investigated modifications to the DQ protocol to improve identification of morphological defects of dog sperm and compared the modified DQ techniques with eosin-nigrosin, Karras, and differential interference contrast microscopy [DIC]). One ejaculate from each of 9 dogs was used. To perform the proposed modified DQ techniques (DQ1 and DQ2), dried semen smears were fixed by immersing for 10 seconds in solution I of DQ and 5 minutes each in solutions II and III of the kit. After the third stain solution, slides in DQ1 were rinsed in water whereas slides in DQ2 were not rinsed but were vertically supported to facilitate stain drainage. Results suggested that the standard DQ protocol overestimated normal sperm and detached heads whereas underestimated abnormal heads and total defects compared to DIC, Karras, eosin-nigrosin, and DQ2. Acrosome abnormalities were only detectable with Karras, DIC, and DQ2. In conclusion, prolonging exposure to DQ staining solutions enhanced sensitivity in sperm morphological evaluation, and avoiding rinse as a final step in the DQ protocol improved visualization of certain acrosome defects in dog sperm. Therefore, modified DQ techniques can serve as a viable alternative for dog sperm morphology evaluation in clinical practice.

Keywords: Canine, semen, dip-quick, breeding soundness examination, male dog

Introduction

Canine breeding market development is ongoing. Primary purpose of dog breeders is to select animals with desired breed standards; therefore, the lack of selection for fertility has become a problem in companion animals, as many purebred dogs are subfertile. Additionally, inbreeding, a common practice in the dog industry, has decreased reproductive capacity, with low semen quality in male dogs.^{1,2} Therefore, breeding soundness examination is essential to determine male dog reproductive ability for breeders.

Andrological examination include physical and genital examinations, and semen collection and analysis.³ Physical examination is essential to determine congenital abnormalities, mating capability, and dog's general health. In contrast, specific genital examination can identify problems of prostate, testes, and penis.^{3,4} More specifically, semen evaluation is essential to predict fertilizing capacity via determining sperm concentration, total and progressive motility, sperm plasma membrane integrity, and sperm morphology.⁵

Sperm are translucent and visible under light microscopy for motility assessment and for sperm concentration via Neubauer chamber. However, sperm morphology evaluation requires special microscopes, such as differential interference contrast microscopy (DIC) or staining techniques to highlight sperm structures.^{1,6} Several stains have been used in clinical practice to identify various cell types. Among staining techniques, the diff-quick stain is considered as a universal cytological stain due to its low cost and availability. However, poor results of sperm smears stained with diff-quick discouraged its use for sperm morphology evaluation.^{7,8} Although increasing the duration of slides exposure to diff-quick stains improved the sensitivity of this assay for dog⁹ and stallion¹⁰ sperm analysis, the sensitivity to detect certain major defects (e.g. head, acrosome, and midpiece) is still low.¹¹ In addition, although studies^{12,13} have used diff-quick staining to assess dog sperm, to the best of our knowledge, there are only a few studies^{3,13,14} that compared various staining methods and their capacity to highlight sperm morphology disorders. Therefore, we compared 2 commonly used staining techniques (Karras and eosin-nigrosin) for sperm morphology evaluation in several species, specialized DIC, and 3 diff-quick staining protocols to

evaluate their efficacy in identifying sperm morphological disorders in dogs.

Materials and methods

Study protocol was approved by the Animal Care and Use Committee of São Paulo State University. Study was conducted at the Department of Veterinary Surgery and Animal Reproduction of São Paulo State University, from March to July 2020.

Sampling strategy and slides staining

Semen samples collected from 9 dogs during students' practical laboratories were used for this study. Dogs belonged to and were housed at the Department of Veterinary Surgery and Animal Reproduction of São Paulo State University and had semen collected by digital stimulation technique. From each semen aliquot, 5 semen smears were prepared and an aliquot was diluted with 10% formol saline for evaluation using DIC microscopy (Leica Microsystems, Wetzlar, Germany). Each smear was stained and evaluated using the techniques described (Table 1).

For modified Karras, dried semen smears were fixed with methanol for 10 seconds and dried on a slide warming table. Afterward, the slides were immersed sequentially in rose Bengal, tannin, and Victoria blue dye for 90, 60, and 20 seconds, respectively, lightly rinsed with water after each stain, and dried at the end.¹⁵ Eosin-nigrosin staining was performed by mixing 1 drop of semen and 1 drop of stain on a slide, then spreading the mixed semen-stain sample similar to blood smear and air-dried.¹⁶

To perform modified diff-quick techniques (DQ1 and DQ2), dried semen smears were fixed by immersing for 10 seconds in solution 1 (fixative-methanol) of diff-quick kit (Instant Prov; Newprov). Afterward, the slide was immersed for 5 minutes in each of the solutions II (buffered solution of eosin Y) and III (buffered solution of thiazine dyes consisting of methylene blue and azure A) of the kit. Following each step, the excess stain was removed from slides by tapping the slides vertically on a paper towel to facilitate stain drainage. After third stain solution, slides in the DQ1 were rinsed in water and then air-dried. In contrast, slides in DQ2 were not rinsed after the final solution but were vertically supported to facilitate stain drainage and air drying.

Slides evaluation

All slides were assessed by 2 experienced and blinded evaluators. Stained semen smears were evaluated under an optical

microscope (Jenamed 2 Zeiss: Carl Zeiss) whereas DIC analysis was carried out with a phase contrast microscope using a wet-mount preparation. Analyses were performed under 1000 x magnification with immersion oil. Two hundred sperm from each sample were evaluated (100 sperm by each evaluator). Abnormalities were classified as head abnormalities, midpiece defects, tail defects, proximal cytoplasmic droplets, distal cytoplasmic droplets, detached heads, and acrosome disorders. Additionally, acrosome anomalies were counted separately, determining the number of sperm with acrosome defects in each 100 sperm.

Data analyses

Data were analyzed with GraphPad Prism 9.0.1. (GraphPad Software, San Diego, CA, USA). Gaussian distribution was evaluated by the Kolmogorov-Smirnov normality test. Sperm morphology defects were tested using Kruskal-Wallis and Dunn's tests. Dogs were accounted as a random effect whereas the staining groups as fixed effects. Significance was set at $p < 0.05$ for all tests and significant tendency was determined with $0.05 < p < 0.1$. Data are presented as mean \pm SEM. Degrees of linear correlations between methodologies were tested using Spearman correlation test. High correlation was considered when $r \geq 0.7$, moderate correlation when $r \geq 0.5$ but < 0.7 , and poor correlation when $r < 0.5$.

Results

Standard diff-quick overestimated the identification of normal sperm and detached heads ($p < 0.05$) and underestimated the identification of abnormal heads and total defects ($p < 0.05$) compared to DIC, Karras, eosin-nigrosin, and modified DQ2 but was similar compared to modified DQ1 ($p > 0.05$). Modified DQ1 presented intermediate results not different from other techniques ($p > 0.05$). All tests had the same efficacy for tail defects, detached head, and proximal and distal droplets ($p > 0.05$). Modified DQ1, standard diff-quick, and eosin-nigrosin techniques were not able to highlight acrosome abnormalities (detached acrosome and absence of acrosome) that were observed using Karras, DIC, and DQ2 ($p < 0.05$, Table 2). However, it is worth noting that the modified DQ2 was enabled detection of detaching acrosome but no absent or swollen acrosome that were observed in the Karras and DIC staining techniques ($p < 0.05$). Representative images of wet-mounted sperm slides evaluated by DIC and sperm smears stained with classical sperm staining techniques Karras and eosin-nigrosin are presented (Figure 1).

Although there were differences in the number of sperm defects observed between staining techniques as described above, a moderate ($r > 0.5$) to high correlation ($r \geq 0.7$) for the number of normal sperm was observed among all techniques

Table 1. Staining techniques and their descriptions

Staining technique	Description
Karras	Modified Karras staining. ¹⁵
Eosin-nigrosin	Manufacturer instruction (BotuVital, Botupharma, Brazil). ¹⁶
Diff-quick (DQ)	Manufacturer instructions (Instant Prov, Newprov, Brazil).
Modified DQ1 (DQ1)	Each smear was immersed for 5 minutes in solutions 2 and 3 of the DQ-staining and rinsed with distilled water at the end. ⁹
Modified DQ2 (DQ2)	Each smear was immersed for 5 minutes in solutions 2 and 3 of the DQ-staining and air-dried. ⁸

Table 2. Mean and standard error of the mean of sperm morphological defects according to the technique performed

Morphology	DIC	Karras	Eosin-nigrosin	Modified DQ1	Modified DQ2	Diff- quick
Normal	75.4±2 ^a	76.1±1.7 ^{ab}	76.4±1.5 ^{ab}	81.3±1.9 ^{bc}	77.8±2.1 ^{ab}	84.3±2.4 ^c
Abnormal heads	3.2±0.6 ^a	2.2±0.4 ^{ab}	2.5±0.4 ^{ab}	1.4±0.3 ^{bc}	2.3±0.6 ^{ab}	0.4±0.2 ^c
Abnormal midpiece	5.8±0.9 ^{ab}	7.4±1.2 ^a	6.4±1.1 ^{ab}	4.3±0.8 ^{bc}	6.6±1.0 ^{ab}	2.4±1.3 ^c
Pathologic tails	7.0±1.4	8.1±1.2	7.6±1.1	7.0±0.9	6.3±1.2	5.8±0.9
Proximal droplet	1.1±0.5	0.5±0.1	0.6±0.2	0.2±0.1	0.2±0.1	0.1±0.1
Distal droplet	4.4±1.9	3.4±1.1	3.1±1.1	3.1±1.6	3.3±1.5	2.2±2.0
Detached head	1.7±0.2 ^a	2.1±0.5 ^a	2.2±0.3 ^a	2.8±0.6 ^{ab}	2.2±0.5 ^a	4.8±0.5 ^b
All defects	24.6±2.1 ^a	23.9±1.7 ^{ab}	23.6±1.5	18.7±1.9 ^{bc}	22.2±2.1 ^{ab}	15.7±2.4 ^c
Acrosome	1.8±0.4 ^a	1.4±0.3 ^a	0 ^b	0 ^b	1.3±0.3 ^a	0 ^b

^{a-c}within a row, means without a common superscript differ ($p < 0.05$)

Modified diff-quick (DQ) 1 and DQ 2 consisted of slide fixation for 10 seconds in solution 1 (fixative-methanol) of diff-quick stain (Instant Prov; Newprov, Brazil). Afterward, the slide was immersed for 5 minutes in each of solutions II (buffered solution of eosin Y) and III (buffered solution of thiazine dyes consisting of methylene blue and azure A of the diff-quick kit). Following each step, excess stain was removed from slides by tapping the slides vertically on a paper towel to facilitate stain drainage. After the third stain solution, slides in modified DQ 1 were rinsed in water and then air-dried. In contrast, slides in modified DQ 2 were not rinsed after the final solution but were vertically supported to facilitate stain drainage and air-dried.

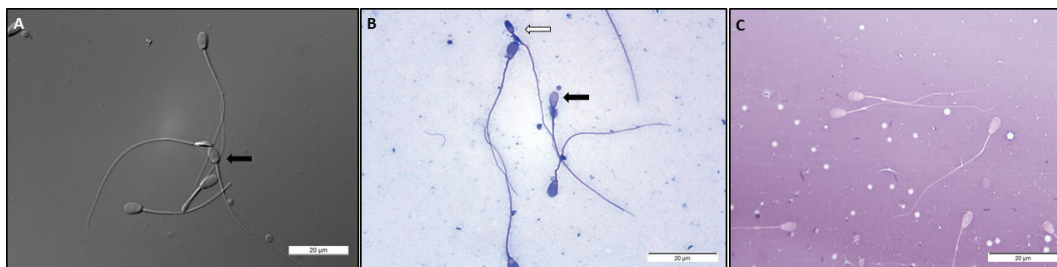


Figure 1. Canine morphological sperm analysis under A. differential interference contrast microscopy, B. Karras, and C. eosin-nigrosin staining techniques. Black arrow indicates sperm with a damaged acrosome and white arrow indicates sperm with an underdeveloped head and damaged midpiece.

(Table 3). However, standard diff-quick had poor correlation compared to DIC and Karras, respectively, for proximal droplets ($r = -0.018$ and $r = 0.395$) and tailless heads ($r = 0.271$ and $r = 0.331$). In addition, DIC, Karras, eosin-nigrosin, and DQ2 had moderate to high correlations between each other to identify all sperm abnormalities ($r > 0.05$, Table 3). Representative images of sperm smears stained with 3 diff-quick techniques are presented (Figure 2).

Discussion

Our objective was to evaluate the ability of various diff-quick staining techniques to highlight morphological abnormalities in dog sperm. Diff-quick is the most commonly available in human and veterinary medicine as a universal cytological stain⁸ and has been reported as a quick and reliable technique for human^{17,18} cat,¹⁹ and bull²⁰ sperm morphology evaluation. However, in contrast, the poor delineation and staining of the cranial pole of the head and the contours of the sperm midpiece affect the sensitivity of diff-quick to identify major defects, such as head, acrosome, and midpiece defects and proximal droplets in stallion⁷ and dog sperm,¹¹ even though basic alterations in sperm morphology (e.g. oversized or undersized heads, bent tails, and tailless heads) and the

presence of immature germ or rounded cells can be detected using this technique.¹¹ The reason for the poor staining of stallion and dog sperm compared to other species (e.g. human^{17,18} cat, Clique ou toque aqui para inserir o texto,¹⁹ and bull²⁰) is not well known, but it has been hypothesized that structural changes in contents of the acrosome among species may be responsible for those differences.²¹ In addition, authors suggested that the overestimation of detached heads in diff-quick stained slides is associated with poor delineation and staining of the cranial pole of the head¹¹ that caused the identification of these sperm as 'normal' detached heads. Similar results have also been reported in stallion sperm stained with diff-quick.⁸

Studies suggested that the increased exposure of the smears to diff-quick staining solutions could improve the sensitivity of this assay in dog⁹ and stallion¹⁰ semen smears analysis. It is worth noting that even though the increased time of smears in solutions II and III of diff-quick staining improved the identification of more specific abnormalities in dog sperm smears, the deletion of the rinsing step at the end of the staining protocol produced more reliable results for sperm morphological analysis. Similar results have also been observed using this technique for staining stallion sperm

Table 3. Correlation of dog sperm morphology assessed with various staining techniques

Technique	DIC	Karras	Eosin-nigrosin	Modified DQ1	Modified DQ2
Normal					
DIC	1.000				
Karras	0.887	1.000			
Eosin-nigrosin	0.846	0.898	1.000		
Modified DQ1	0.798	0.657	0.708	1.000	
Modified DQ2	0.891	0.812	0.734	0.742	1.000
Diff-quick	0.882	0.782	0.796	0.909	0.800
Abnormal heads					
DIC	1.000				
Karras	0.811	1.000			
Eosin-nigrosin	0.901	0.868	1.000		
Modified DQ1	0.656	0.317	0.546	1.000	
Modified DQ2	0.821	0.864	0.909	0.404	1.000
Diff-quick	0.743	0.540	0.636	0.859	0.476
Abnormal midpieces					
DIC	1.000				
Karras	0.892	1.000			
Eosin-nigrosin	0.909	0.937	1.000		
Modified DQ1	0.717	0.834	0.809	1.000	
Modified DQ2	0.808	0.923	0.798	0.690	1.000
Diff-quick	0.536	0.783	0.621	0.692	0.759
Tail defects					
DIC	1.000				
Karras	0.926	1.000			
Eosin-nigrosin	0.940	0.967	1.000		
Modified DQ1	0.886	0.779	0.821	1.000	
Modified DQ2	0.904	0.855	0.894	0.763	1.000
Diff-quick	0.913	0.792	0.852	0.859	0.872
Proximal droplets					
DIC	1.000				
Karras	0.986	1.000			
Eosin-nigrosin	0.926	0.926	1.000		
Modified DQ1	0.396	0.445	0.496	1.000	
Modified DQ2	0.973	0.955	0.945	0.496	1.000
Diff-quick	-0.101	-0.080	-0.227	-0.158	-0.172
Distal droplets					
DIC	1.000				
Karras	0.974	1.000			
Eosin-nigrosin	0.977	0.982	1.000		
Modified DQ1	0.975	0.987	0.969	1.000	
Modified DQ2	0.979	0.985	0.966	0.994	1.000
Diff-quick	0.959	0.972	0.981	0.941	0.939

(Continued)

Table 3. (Continued)

Technique	DIC	Karras	Eosin-nigrosin	Modified DQ1	Modified DQ2
Tailless heads					
DIC	1.000				
Karras	0.822	1.000			
Eosin-nigrosin	0.636	0.634	1.000		
Modified DQ1	0.741	0.793	0.521	1.000	
Modified DQ2	0.711	0.523	0.304	0.545	1.000
Diff-quick	0.168	0.074	0.139	0.408	0.294
Total defects					
DIC	1.000				
Karras	0.862	1.000			
Eosin-nigrosin	0.904	0.933	1.000		
Modified DQ1	0.798	0.718	0.769	1.000	
Modified DQ2	0.748	0.709	0.751	0.657	1.000
Diff-quick	0.890	0.803	0.867	0.897	0.761
Acrosome defects					
DIC	1.000
Karras	0.834	1.000	.	.	.
Modified DQ1	0.746	0.643	.	.	1.000

Modified diff-quick (DQ) 1 and DQ 2 consisted of 10 seconds of fixation in solution 1 (fixative-methanol) of diff-quick stain (Instant Prov; Newprov, Brazil). Afterward, the slide was immersed for 5 minutes in each of solutions II (buffered solution of Eosin Y) and III (buffered solution of thiazine dyes consisting of methylene blue and Azure A) of the diff-quick kit. Following each step, excess stain was removed from slides by tapping the slides vertically on a paper towel to facilitate stain drainage. After the third stain solution, slides in the modified DQ 1 were rinsed in water and then air-dried. In contrast, slides in modified DQ 2 were not rinsed after the final solution but were vertically supported to facilitate stain drainage and air-dried.

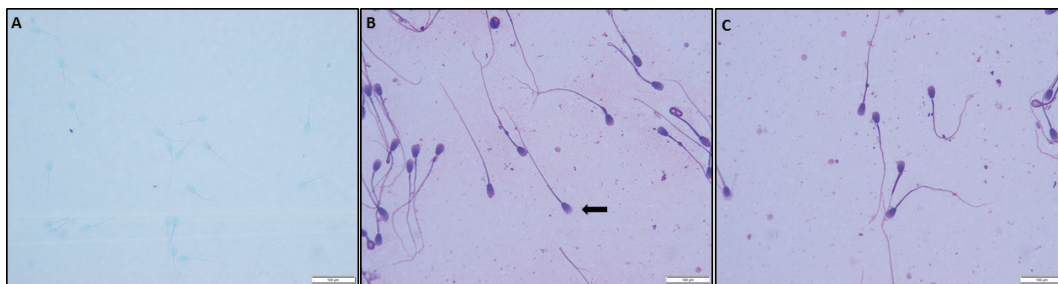


Figure 2. Canine sperm smears stained with A. standard diff-quick, B. modified diff-quick 1, and C. modified diff-quick 2. slides were assessed using an optical microscope. Black arrow indicates sperm with a detached acrosome.

smears when compared to the standard diff-quick technique.⁸ Under-stained sperm have also been associated if a slide with air-dried semen smear is dipped several times in each of 3 solutions, as recommended for blood smear staining¹⁰ that may corroborate with the findings of the present study in which sperm undergo a different staining process compared to cytological smears.

Another interesting finding of this study was that the proposed modified diff-quick technique (DQ2) enabled identification of sperm with detaching acrosome. Although diff-quick has been suggested as an easy and effective alternative for

human sperm analysis with the ability to highlight acrosome abnormalities,¹⁸ in domestic animals, this staining technique has been less effective in identifying acrosome defects compared to other staining methods.^{8,14} However, it is also worth noting that even though the modified technique proposed herein highlighted sperm with detaching acrosome, besides DIC and Karras, no other method was able to identify sperm with an absent or swollen acrosome in the present study. An increment in time in each stain (> 5 minutes) associated with not rinsing the slides might result in a better outcome for viewing acrosome abnormalities in dogs. However, future studies are needed to address the effectiveness of diff-quick

stain to highlight the cranial region of sperm head or possible acrosome abnormalities if slides were left longer in the stains.

Conclusion

Diff-quick staining sensitivity for sperm morphological evaluation can be improved by prolonged exposure to the staining solutions. This technique has proven to be an alternative for assessing dog sperm morphology and can easily be introduced in clinical practice, although some care should be taken for acrosome evaluation. Although no rinsing of slides at the end of staining protocol (modified DQ 2) improved the visualization of some major defects (e.g. detaching acrosome) compared to the technique suggested,⁹ the current technique was unable to highlight acrosome defects in the same way as other standard methods for sperm evaluation, such as DIC and Karras.

Conflict of interest

None to report.

References

1. Dai C, Zhang Z, Shan G, et al: Advances in sperm analysis: techniques, discoveries and applications. *Nat Rev Urol* 2021;18: 447–467. doi: 10.1038/s41585-021-00472-2
2. Marelli SP, Beccaglia M, Bagnato A, et al: Canine fertility: the consequences of selection for special traits. *Reprod Domest Anim* 2020;55:4–9. doi: 10.1111/rda.13586
3. Lopate C: Applied animal andrology: dog. In: Chenoweth PJ, Lorton S: editors. *Manual of Animal Andrology*. Wallingford, UK: CABI International; 2022. p. 160–186.
4. Soderberg SF: Canine breeding management. *Vet Clin North Am Small Anim Pract* 1986; 16:419–433. doi: 10.1016/S0195-5616(86)50051-6
5. Kolster KA: Evaluation of canine sperm and management of semen disorders. *Vet Clin North Am Small Anim Pract* 2018;48:533–545. doi: 10.1016/j.cvsm.2018.02.003
6. Arruda R, Silva D, Affonso E, et al: Methods for assessment of sperm morphology and function: actual moment and future challenges. *Rev Bras Reprod Anim* 2011;35:145–151.
7. Brito LFC, Greene LM, Kelleman A, et al: Effect of method and clinician on stallion sperm morphology evaluation. *Theriogenology* 2011;76:745–750. doi: 10.1016/j.theriogenology.2011.04.007
8. Segabinazzi LG, Mercês Chaves LF, Araujo EA, et al: Dip quick staining modified for morphological evaluation to equine spermatozoa. *J Equine Vet Sci* 2017;55:71–75. doi: 10.1016/j.jevs.2017.02.015
9. Kustritz M: Determining the optimal age for gonadectomy of dogs and cats. *J Am Vet Med Assoc* 2007;231:1665–1675. doi: 10.2460/javma.231.11.1665
10. Pozor MA, Zambrano GL, Runcan E, Macpherson M: Usefulness of Dip Quick Stain in evaluating sperm morphology in stallions. *Proc Am Ass Equine Practnrs* 2012;58:506–510.
11. Randall CJ, Negri AP, Quigley KM, et al: Sexual production of corals for reef restoration in the Anthropocene. *Mar Ecol Prog Ser* 2020;635:203–232. doi: 10.3354/meps13206
12. Soler C, Alambiaga A, Martí MA, et al: Dog sperm head morphometry: its diversity and evolution. *Asian J Androl* 2017;19: 149–153. doi: 10.4103/1008-682X.189207
13. Wysokińska A, Wójcik E, Chłopik A: Evaluation of the morphometry of sperm from the epididymides of dogs using different staining methods. *Animals* 2021;11:1–11. doi: 10.3390/ani11010227
14. Surmacz P, Niwinska A, Kautz E, et al: Comparison of two staining techniques on the manual and automated canine sperm morphology analysis. *Reprod Domest Anim* 2022;57:678–684. doi: 10.1111/rda.14100
15. Papa FO, Alvarenga MA, Carvalho IM, et al: Karras spermatic coloration modified by the use of barbatimão (*Stryphnodendrum barbatiman*). *Arq Bras Med Vet Zootec* 1988;40:115–123.
16. Hancock JL: A staining technique for the study of temperature-shock in semen. *Nature* 1951;166: 323–324. doi: 10.1038/167323b0
17. Oehninger S, Kruger TF: Sperm morphology and its disorders in the context of infertility. *Fertil Steril* 2020;2:75–92. doi: 10.1016/j.xfnr.2020.09.002
18. Kruger TF, Ackerman SB, Simmons KF, et al: A quick, reliable staining technique for human sperm morphology. *Syst Biol Reprod Med* 1987;18:275–277. doi: 10.3109/01485018708988493
19. Mota PC, Ramalho-Santos J: Comparison between different markers for sperm quality in the cat: diff-quick as a simple optical technique to assess changes in the DNA of feline epididymal sperm. *Theriogenology* 2006;65:1360–1375. doi: 10.1016/j.theriogenol.2005.08.016
20. Bastos YHGB, da Silva CF, Gomes GM, et al: Evaluation of different coloration techniques for smears obtained by aspiration biopsy puncture of bull testis. *Rev Saúde* 2015;6:05. doi: 10.21727/rs.v6i2.961
21. Foster JA, Gerton GL: The acrosomal matrix. *Adv Anat Embryol Cell Biol* 2016;220:15–33. doi: 10.1007/978-3-319-30567-7_2