

Preputial stoma: A novel surgical approach for semen collection in bulls with phimosis due to preputial stenosis; three cases (2007–2014)

Chance L. Armstrong, Dwight F. Wolfe, Jennifer H. Koziol, Robert L. Carson
College of Veterinary Medicine, Auburn University, Auburn, AL

Summary

Three bulls were presented to the Auburn University Large Animal Teaching Hospital Food Animal Section for inability to extend the penis following prior preputial injury. Each bull had stenosis of the prepuce from excessive scar tissue from previous preputial laceration. In each bull the extent and location of the stenosis prevented circumcision or preputial scar revision to return the bull to breeding soundness. The goal of the owners was either to allow the bull to live comfortably or to be able to collect semen for cryopreservation. This report describes a surgical technique to satisfy those goals.

Keywords: Bovine, preputial stoma surgery, prepuce, semen collection, preputial laceration

Background

Preputial lacerations most often occur during coitus in breeding bulls and these injuries may result in significant financial loss to both beef and dairy producers.¹ These injuries usually require prolonged sexual rest and medical and or surgical treatment options are often expensive and prolonged in nature or may result in culling an animal that may have significant genetic and monetary value.

Severe preputial injuries or frostbite are more common in *Bos indicus* breeds and crosses of those breeds but may also occur in bulls of *Bos taurus* breeds.¹ The preputial anatomy of *Bos indicus* bulls increases their risk of trauma to the area compared to bulls of *Bos taurus* breeds. This is due to the fact that bulls of *B. indicus* breeds have a more pendulous sheath with a larger preputial orifice, a longer prepuce relative to the length of the free portion of the penis, and a lower preputial angle in relation to the ventrum of the bull.¹ Naturally polled bulls are also at increased risk for developing preputial disease because of lack of retractor preputial muscles that prevent chronic eversion of the prepuce.²

Bulls with preputial injuries often require a combination of medical and surgical management to correct pathology of the prepuce. Preputial injuries most often occur in the mid-preputial area or near the attachment of the prepuce to the free portion of the penis.¹ The most common injuries are preputial laceration with cellulitis or perhaps secondary to retropreputial abscess or frostbite of the prepuce. The prognosis for return to breeding soundness is dependent on many factors including the degree in which the epithelial covering of the prepuce is damaged, the extent of damage to the peripenile elastic tissue, the amount of normal prepuce remaining, and location of the injury within the prepuce; all determine the prognosis for successful return to breeding soundness.¹

Bulls with a preputial injury or frostbite often develop extensive scar tissue such that there is insufficient length of healthy prepuce for scar revision or preputial reconstruction or circumcision.¹ The creation of a stoma of the preputial cavity through the sheath may allow sufficient penile protrusion for semen collection for cryopreservation or fresh transfer. Additionally, in the authors' experience two bulls successfully achieved coitus following this surgical procedure.

Surgical creation of a preputial stoma can be accomplished with the bull in lateral recumbency either under general anesthesia or with light sedation in combination with an internal pudendal nerve block. An internal pudendal nerve block can be performed by first clipping and surgically preparing the skin at the ischiorectal fossa on both sides. A 14 gauge, 1.25 cm needle is inserted through the desensitized skin at the ischiorectal fossa to serve as a cannula. An 18 gauge, 10-15 cm spinal needle is then directed through the cannula to the pudendal nerve. The operator's left hand is placed in the rectum to the level of the wrist and the fingers are directed laterally and ventrally to identify the right lesser sacrosclatic foramen. The lesser sciatic foramen is first identified and the internal pudendal nerve can be readily identified lying on the ligament immediately cranial and dorsal to the foramen and approximately one finger's width dorsal to the pudendal artery. This structure can be readily palpated a finger's width

ventral to the nerve. Once the pudendal nerve is located, 20 mL of local anesthetic is deposited around the nerve. The procedure is repeated for the left internal pudendal nerve using the right hand.

Clip and prepare the sheath for aseptic surgery and make a longitudinal elliptical incision through the skin on the ventral aspect of the sheath. This incision should be just proximal to the stenotic scar tissue in the preputial cavity. The diameter of the stoma should be sufficiently large to allow the free portion of the penis to extend but not large enough that the remaining prepuce could prolapse through the opening. Discard the excised elliptical skin and continue dissection through the peripenile elastic layers to the internal lamina of the prepuce (Figure 1). Elevate the prepuce through the opening in the sheath and incise the prepuce near the distal end of the elliptical incision. Exteriorize the free portion of the penis through the incision by grasping the glans penis with sponge forceps. Using #0 absorbable suture appose the preputial epithelium to the skin of the sheath around the periphery of the stoma with a simple interrupted suture pattern (Figure 2).

Finally, suture a 2.5cm wide by 10cm long Penrose drain over the free portion of the penis to allow post-operative urine drainage away from the incision (Figure 3). Remove the drain ten days postoperatively and ensure the bull has 60 days of strict sexual rest prior to an attempt at semen collection.

Case presentation

Case 1

A ten year-old Brahman bull was presented with a history of preputial laceration approximately six months previously that had been managed medically by the referring veterinarian. The bull was referred to the teaching hospital at Auburn University because of preputial swelling that impeded urination. Upon presentation the bull had phimosis and the lumen of the prepuce was one cm in diameter due to excessive scar tissue near the end of the sheath. The bull underwent a resection and anastomosis procedure to remove the stenotic area of prepuce. The bull recovered from the surgery uneventfully, but later scar tissue developed at the surgical site once again creating stenosis that threatened to impede the bull's ability to void urine. Surgery for creation of the preputial stoma was performed under light sedation using 0.1 mg/kg xylazine with the bull in lateral recumbency with the aid of a pudendal nerve block as previously described.⁴

Case 2

A two year old Angus bull was presented with a history of a preputial laceration that had been repaired by resection and anastomosis of the prepuce by the referring veterinarian. The bull later developed a preputial stricture that precluded extension of the penis. The stricture was located approximately eight cm inside the preputial opening and had a luminal diameter of one cm. The bull displayed retention of urine in the preputial cavity proximal to the stricture. Surgery for creation of the preputial stoma was performed under general anesthesia. The anesthetic protocol involved a preanesthetic of 50mg xylazine IM, followed by induction with 1000 mg ketamine and 50 mg xylazine IM, and the patient was maintained on isoflurane in lateral recumbency for the entirety of the surgery.

Case 3

A three year-old Santa Gertrudis bull presented with severe preputial prolapse and upon examination a preputial laceration was identified. Following medical management to reduce swelling and cellulitis the damaged preputial tissue was removed using a preputial resection and anastomosis procedure and the bull was discharged following the surgery. The bull returned after 60 days of sexual rest for evaluation of the surgical site and a breeding soundness evaluation. At that time it was discovered that a stricture had formed that precluded the bull from fully extending the penis. Due to the previous procedure the prepuce lacked sufficient length to perform a second resection and anastomosis (Figures 3 and 4). This bull had surgery performed under light sedation and an internal pudendal nerve block as described previously.

Treatment and outcome

Each of these bulls suffered severe phimosis due to stenosis of the preputial cavity following injury or surgical repair of preputial lacerations by resection and anastomosis of the damaged preputial tissue. For each of these cases the owners wished to either allow the bull to live without difficult urination or to continue to collect semen. Each of the bulls underwent either general or local anesthesia for the creation of the preputial stoma. In each case the bull recovered from anesthesia and surgery uneventfully. This procedure and the following outcomes are the first to be reported to our knowledge and have to date been the only attempts made by the authors for the described method.

The goal for the bull in Case 1 was for him to live without the complication of urine accumulation within the sheath proximal to the stenotic area of the prepuce. The bull underwent surgery under light sedation and a pudendal nerve block. There were no complications during or following this procedure. The bull was able to urinate unimpeded and the owner reported that the bull unexpectedly bred two cows resulting in one pregnancy.

The goal for the bull in Case 2 was to collect semen for cryopreservation at a semen processing facility. After the stoma site healed semen from the bull was collected successfully via electroejaculation. Semen collected met the standards set forth by the Society for Theriogenology prior to cryopreservation.

The goal for the bull in Case 3 was to collect semen for cryopreservation. The goal was achieved and the owner was able to bank several thousand straws of semen following collection. It was later reported by the referring veterinarian that the bull achieved intromission with several cows that pregnancies resulted.

Discussion

Acquired preputial injuries in bulls are a common problem encountered in clinical practice. Stricture formation, a complication following correction with medical and/or surgical procedures, is not uncommon. It is the observation at the Auburn University Large Animal Teaching Hospital that a significant increase in post-operative complications are seen in the summer months when the ambient temperature and humidity are both high. Historically, bulls have gone to slaughter following the formation of a stricture within the prepuce that was not correctable by other means. Often these bulls are not candidates for a second surgical procedure because of inadequate preputial length that would preclude the necessary minimum of two times the length of the free portion of the penis to achieve full extension.³ The initial injury (trauma, frostbite, etc.) may also preclude an initial surgery to correct the fibrotic area because of the length of the prepuce. The authors have demonstrated that the creation of a preputial stoma in cases of stricture formation may be not only a salvage procedure, but also extend the breeding life of some sires through cryopreservation of semen and in some cases live cover. This procedure may be considered as the primary surgical procedure depending on wishes of the client and financial considerations as this procedure typically cost one-half to one-third of resection and anastomosis. It should be noted that bulls that achieve intromission following this procedure will likely be those with excellent libido. Semen collection via artificial vagina and electroejaculation are both possibilities after healing of the surgical site.

Learning points

- Preputial injuries are common in bulls in pasture breeding systems.
- Preputial stoma surgery should be considered as an option in bulls with preputial stricture precluding extension of the penis.
- The genetics of bulls can be preserved following this procedure via cryopreservation or by natural breeding.

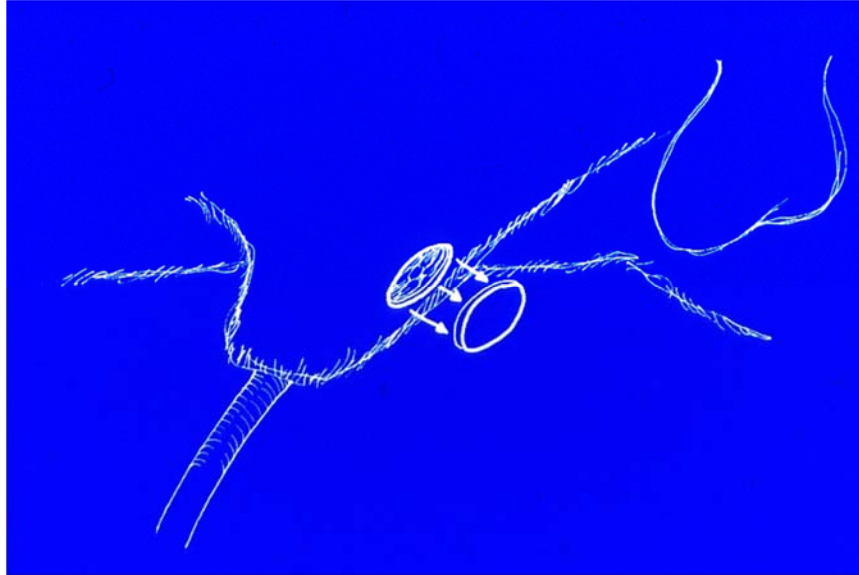


Figure 1. Schematic demonstrating stoma placement on the ventral aspect of sheath.

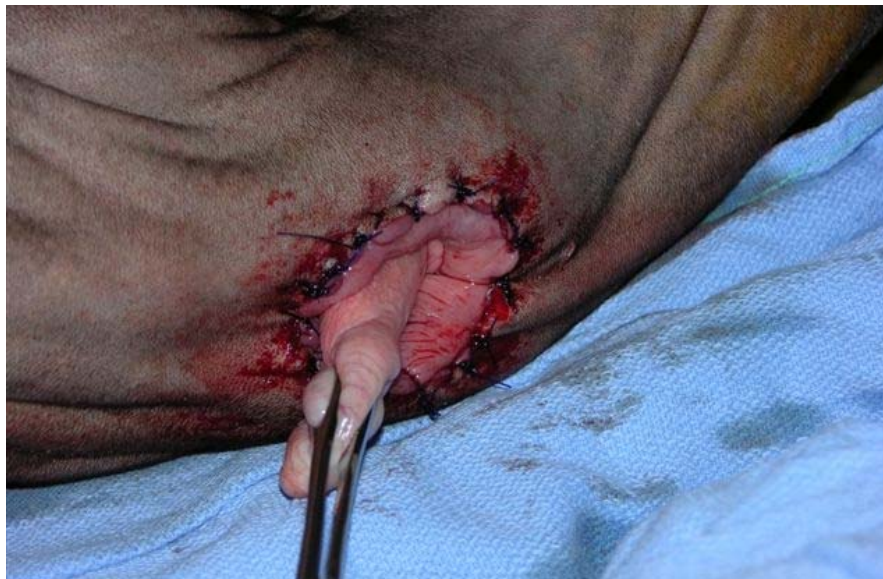

Figure 2. Immediate postoperative image of the preputial stoma created in case 1.

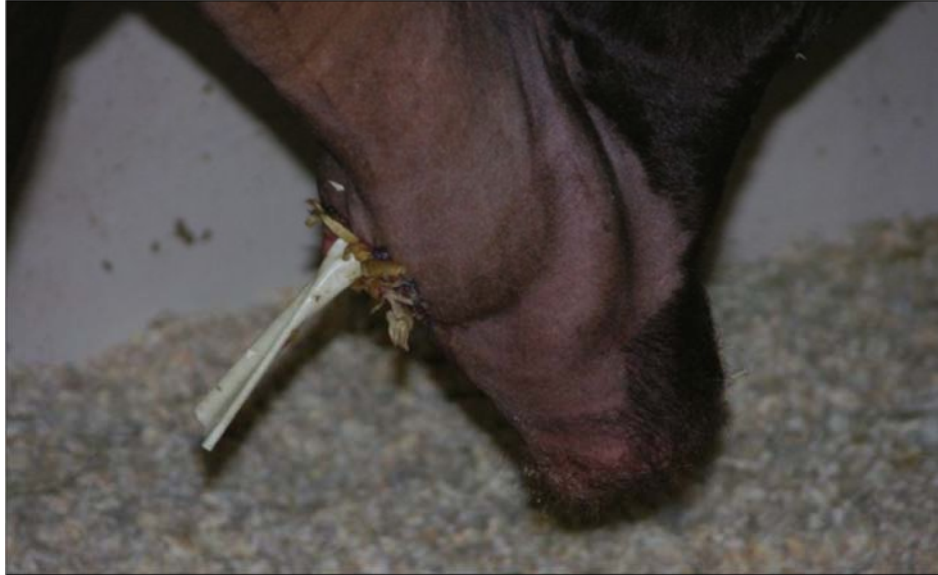

Figure 3. Penrose drain exiting stoma allowing urine drainage away from incision site.



Figure 4. Note position of stoma along the ventral sheath in bull described in case 3.

References

1. Wolfe DF, Beckett SD, Carson RL: Acquired conditions of penis and prepuce. In: Wolfe DF, Moll HD, editors. Large animal urogenital surgery. 2nd ed. Baltimore: Williams & Wilkins; 1999. p. 237-272.
2. Long SE: Eversion of the preputial epithelium in bulls at artificial insemination centres. *Vet Rec* 1969;84:495-499.
3. Walker DF, Vaughan JT: Bovine and equine urogenital surgery. Philadelphia: Lea & Febiger; 1980. p. 277.
4. Lin HC, Walz PH: Farm animal anesthesia. Hoboken (NJ): John Wiley & Sons; 2014. p. 278.

(Editor's note: Photographs in this manuscript are available in color in the online edition of *Clinical Theriogenology*.)

