

## Vaginal stricture as an unusual case of dystocia in a dairy cow

Allan J. Gunn

School of Animal and Veterinary Sciences, and the Graham Centre for Agricultural Innovation,  
Charles Sturt University, Wagga Wagga, NSW, Australia

### Abstract

Dystocia (difficult birth) is a relatively common occurrence in bovine reproduction. In one study on dairy farms in the USA 51.2% heifers and 29.4% of cows required assistance at parturition.<sup>1</sup> Causes include abnormalities of the birth canal such as a narrow vagina. This is a report of a case of a stricture in the caudal vagina in a multiparous Friesian/Holstein cow leading to dystocia and delivery of the fetus by cesarean section. To the author's knowledge, a vaginal stricture ('pseudocervix') has not been reported as a cause of dystocia in cattle.

**Keywords:** Dystocia, cow, multiparous, vaginal stricture, pseudocervix

### Case report

A multiparous Friesian/Holstein cow in good body condition (3/5) had failed to deliver a calf after approximately 24 hours of what appeared to be the second stage of parturition. She had been bred by artificial insemination approximately 280 days prior to presentation. On examination it was not possible to palpate the calf due to a complete obstruction/stricture of the reproductive tract. The stricture was cranial to the vestibulo-vaginal sphincter, and was impenetrable despite considerable manual force and digital manipulation. Fetal membranes and fluid were absent from the caudal reproductive tract. A small (approximately 1-2mm in diameter) aperture was palpable in the central region of the obstruction. *Per rectum* examination confirmed the presence of a calf in the uterus; ultrasonographic evaluation was not performed in this case because of unavailability. It was not possible to determine the viability of the calf.

Initially it was assumed the stricture was due to an incompletely dilated cervix, as the calf was not palpable *per vaginam*. Unfortunately, a speculum examination was not performed. In retrospect, it is unlikely that a speculum examination would have been beneficial at presentation. However, a vestibulo-vaginal examination postpartum or prior to breeding, would more likely have led to detection of this potential problem prior to impregnation of the cow.

A decision was made to undertake a cesarean section in order to deliver the fetus, and determine the reason for the obstruction. A dead, but anatomically normal, fetus was removed via laparotomy and hysterotomy. Gross external signs (cloudy cornea) suggested the fetus had been dead for longer than 12 hours based on reports on the changes associated with autolysis.<sup>2</sup> The cow was subjected to euthanasia, as the prognosis for a live cow after caesarean section with a dead fetus is not good,<sup>3</sup> and she was unlikely to conceive again.

Postmortem the reproductive tract was removed from the cow, and examined (Figure). The cervix was open with the internal cervical aperture being approximately 5 cm in diameter, and the vagina was stained brown. It was coated by a brown colored amorphous substance that was easily removed. This material, presumed to be meconium, suggested that the fetal membranes had ruptured during dystocia. Approximately 0.5cm cranial to the external urethral opening was a small (1-2mm) aperture within a thickened fibrotic vestibule caudal to the vestibulo-vaginal sphincter. The cranial vestibule was obviously bruised, probably as a result of iatrogenic trauma associated with the dystocia.

Grossly, sectioning the vestibule and the area of the stricture revealed firm, white, non-yielding tissue suggestive of fibrous tissue, approximately 5 mm thick in most places (Figure 1). This stricture at the caudal vagina was the reason for dystocia in this cow.

Cervical causes of dystocia have been reported in the doe,<sup>4</sup> the ewe,<sup>5</sup> and in cattle.<sup>6-8</sup> Typically they are a manifestation of dystocia due to some other primary cause such as uterine inertia, malposition, malpresentation, or malposture of the fetus.<sup>9</sup> Relaxation of the vagina is an important part of the preparation for birth in the cow. The presence of scar tissue from a previous calving injury, congenital stenosis of the vagina, obstruction by embryonic remnants, a hymen, abscess or cyst formation have been reported as vaginal causes of dystocia.<sup>8</sup> Unfortunately the owner was unable to verify if the cow had a dystocia previously, and/or was difficult to inseminate for this pregnancy.

To the author's knowledge this is the first reported case of an impenetrable fibrotic vaginal stricture resulting in dystocia in a dairy cow. The reason for the stricture could not be ascertained by gross examination of the reproductive tract. Histology was not carried out on this occasion and is unlikely to have elucidated the etiology. Previous trauma to the caudal reproductive tract, such as from a previous dystocia, with fibrosis and contraction of the caudal vestibule is presumed to be the most likely cause of the stricture. This report adds another previously unreported differential diagnosis to the list of reasons for dystocia due to caudal reproductive tract obstruction in the cow.

**Acknowledgements**

The author thanks Dr. Stewart Scott and the owner for their assistance in this case; Rob Lofstedt and Scott Norman for assistance in assessing the article; and Lee-Anne McInerney for her library assistance in preparing the document.

No funding was required for this report, nor has it been presented at any meetings/conferences.

**References**

1. Lombard JE, Garry FB, Tomlinson SM, et al: Impacts of dystocia on health and survival of dairy calves. *J Dairy Sci* 2007;90:1751-1760.
2. Dillman RC, Dennis SM: Sequential sterile autolysis in the ovine fetus: macroscopic changes. *Am J Vet Res* 1976;37:403-407.
3. Lyons NA, Karvountzis S, Knight-Jones TJD: Aspects of bovine caesarean section associated with calf mortality, dam survival and subsequent fertility. *Vet J* 2013;197:342-350.
4. Braun Jr W: Parturition and dystocia in the goat. In: Youngquist RS, Threlfall WR, editors. *Current therapy in large animal theriogenology*. 2nd ed. St. Louis: WB Saunders; 2007. p. 555-558.
5. Menzies PI: Lambing management and neonatal care. In: Youngquist RS, Threlfall WR, editors. *Current therapy in large animal theriogenology*. 2nd ed. St. Louis: WB Saunders; 2007. p. 680-695.
6. Wehrend A, Bostedt H: Species-specific significance of the cervix as a cause of dystocia. *Tierarztliche Umschau*. 2005;60:7-12.
7. Azawi OI, Naoman UT, Al-Kass ZM, et al: Misoprostol treatment of dystocia due to incomplete dilatation of the cervix in a cow: a case report. *Iraqi J Vet Sci* 2011;25:97-98.
8. Jackson PGG: *Handbook of veterinary obstetrics*. 2nd ed. Edinburgh: WB Saunders Ltd.; 2004.
9. Norman S, Youngquist R: Parturition and dystocia. In: Youngquist RS, Threlfall WR, editors. *Current therapy in large animal theriogenology*. 2nd ed. St. Louis: WB Saunders; 2007. p. 310-335.

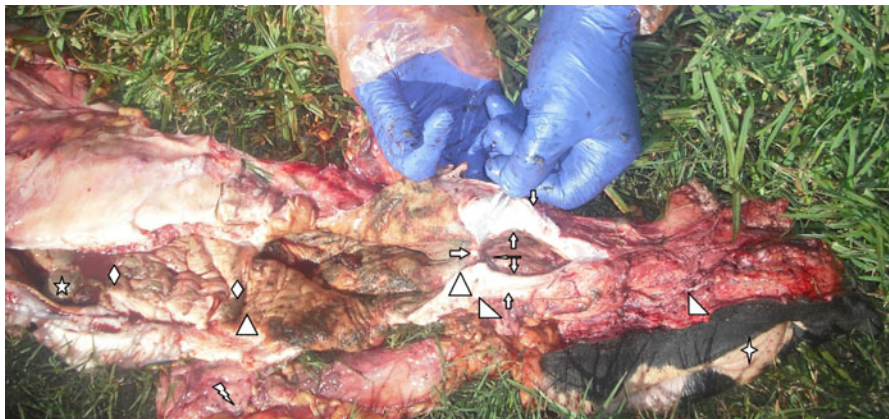
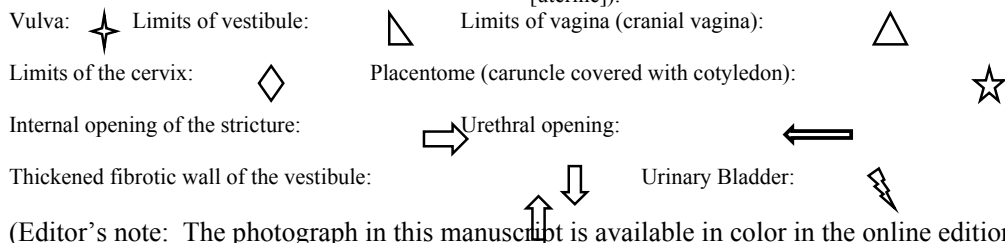


Figure. A photograph illustrating the caudal vaginal stricture ("pseudocervix") of the reproductive tract of the case presented with dystocia. There is obvious fibrosis of the vestibular walls and constriction of the caudal vagina. (Left is cranial [uterine]).



(Editor's note: The photograph in this manuscript is available in color in the online edition of *Clinical Theriogenology*.)