

Perineal laceration following obstructive dystocia in a bitch

Jenna C. Dockweiler, Soon Hon Cheong, Robert O. Gilbert*

Department of Clinical Sciences, College of Veterinary Medicine, Cornell University, Ithaca, NY

Summary

A three-year-old longhaired Whippet was presented after whelping for evaluation of vaginal hemorrhage. Her owners reported an obstructive dystocia which had spontaneously resolved. On examination, a second-degree perineal laceration was discovered. Surgical repair was performed five weeks after the initial injury and was successful in closing the wound. To the authors' knowledge, this is the first report of perineal laceration and the first description of its repair in a bitch.

Keywords: Perineal laceration, bitch, dystocia

Background

Dystocia in the bitch is not uncommon, affecting approximately 16% of canine pregnancies and accounting for 56% of reproductive emergencies.^{1,2} Causes for dystocia include maternal causes such as primary uterine inertia or secondary uterine inertia and fetal causes such as oversized fetuses causing physical obstruction of the birth canal.³ A retrospective study evaluated maternal vs. fetal causes of dystocia and found fetal causes represent only 24.7% of dystocia causes.⁴ The most common fetal cause of dystocia in this study was malpresentation.⁴ Of all dystocia cases, 60-80% are ultimately treated by cesarean section.⁵

The present case describes a bitch with obstructive dystocia that spontaneously resolved, but resulted in a perineal laceration. To the authors' knowledge, this condition has not been reported in the bitch.

Case presentation

A three-year-old primiparous longhaired Whippet bitch was presented to the Cornell University Hospital for Animals for evaluation of postpartum vaginal and vulvar bleeding. Her owners reported the first puppy was malpostured, and initially only a single limb was visible outside the vulva. After several minutes of active contractions that failed to advance the obstructed fetus, a second fetus was delivered simultaneously alongside the malpostured fetus and the bitch began to bleed from her caudal reproductive tract. She whelped seven additional puppies without difficulty before she was presented for evaluation. All puppies survived and were apparently healthy.

She was bred by natural mating on days 3 and 5 after the LH peak based on progesterone timing. No abnormalities of the reproductive tract were noted on digital vaginal examination or vaginal speculum examination prior to breeding.

On presentation, the bitch was bright, alert, and responsive. Her vital signs and general physical condition were within normal limits. On examination of the vulva, a tear extending straight dorsally approximately 2.5 cm from the dorsal commissure was noted. The tear extended to the vestibulovaginal junction. Digital vaginal examination revealed a full-thickness laceration of the dorsal commissure of the vulva and caudal vagina with involvement of the perineal body (second-degree perineal laceration). No communication with the rectum was noted on vaginal or rectal examination. Antibiotics (cephalexin 25 mg/kg) and analgesic medications (tramadol 3 mg/kg) were administered for two weeks in preparation for surgical repair.

Treatment

Repair of the laceration was delayed until five weeks postpartum to ensure the tissue was viable. Appearance of the laceration at the time of surgical repair is depicted in Figure 1. The patient was anesthetized using propofol to effect for induction and was maintained on isoflurane inhalant. She was

* Current address: Ross University School of Veterinary Medicine, St. Kitts, West Indies

placed in sternal recumbency and the surgical area was clipped and aseptically prepared. The laceration was located and the edges of the wound were freshened using Metzenbaum scissors (Figure 2). The muscles and mucosa were closed in a simple continuous pattern using poliglecaprone suture (Monocryl®, Ethicon, Somerville, NJ). The skin was closed using non-absorbable suture (Ethilon®, Ethicon, Somerville, NJ) in a simple interrupted pattern (Figure 3). Recovery from anesthesia was uneventful.

Outcome

The bitch removed the skin sutures eight days after surgery, but the underlying suture layer remained intact. The skin was allowed to heal by second intention. The wound healed without complication. Based on digital vaginal examination after repair, the authors feel this bitch could be bred naturally and whelp without complication. The owner does not plan to breed her a second time.

Discussion

Perineal lacerations are classified as first-degree, second-degree, or third-degree depending on which tissues are involved. A first-degree laceration is characterized by involvement of the vulvar mucosa only.⁶ A second-degree laceration is characterized by involvement of the vulvar mucosa and the perineal body.⁶ A third-degree laceration involves tearing of the vulvar mucosa, perineal body, rectum, and anal sphincter.⁶

Of the major domestic species, the mare is most likely to suffer a perineal laceration following delivery of a foal. Heavily muscled or primiparous mares are more often affected.⁶ Perineal laceration may result during unassisted delivery of a large foal, with overzealous assistance at delivery, or as a sequela to dystocia.^{6,7} Third-degree perineal lacerations may result from the fetal hoof catching on the dorsal aspect of the vagina at the vestibulovaginal junction and penetrating through the vagina and rectum.⁷ In most cases, repair is attempted at six to eight weeks after delivery to allow for the resolution of swelling and granulation of the wound.^{6,7} Although these injuries are not life-threatening, future fertility is affected if the wound is not appropriately repaired.⁶

Reported complications of dystocia in the bitch include metritis, uterine rupture with secondary septic peritonitis, and fetal or maternal death.^{5,8,9} To the authors' knowledge there are no reports of perineal laceration in the bitch, although perineal hernia with retroflexion of the urinary bladder is a reported sequela of dystocia.¹⁰

Episiotomy is described as a treatment for obstructive dystocia, but it is not commonly utilized.⁵ In this case, it is possible the perineal trauma in the bitch would have been less severe if an episiotomy were performed or if obstetrical manipulations had corrected the malposture of the first fetus.

The present case describes a second degree perineal laceration resulting from an obstructive dystocia in a bitch. This condition and its repair has not previously been reported in this species.

Learning points

- Perineal laceration is a possible sequela to dystocia in the bitch.
- Surgical repair of the laceration is relatively simple, although no information on future fertility of bitches with perineal lacerations exists in the literature at this time.
- Owners or others who attend whelpings should be counseled on proper fetal presentation, position, and posture, and given instructions on how to manipulate a fetus and when to seek veterinary attention.

Conflict of interest

The authors have no conflicts of interest or sources of funding to disclose.

References

1. Bergström A, Nødtvedt A, Lagerstedt AS, et al: Incidence and breed predilection for dystocia and risk factors for cesarean section in a Swedish population of insured dogs. *Vet Surg* 2006;35:786-791.

2. Martins-Bessa A, Cardoso L, Costa T, et al: Reproductive emergencies in the bitch: a retrospective study. *J Hellenic Vet Med Soc* 2015;66:231-240.
3. Münnich A, Küchenmeister U: Dystocia in numbers – evidence-based parameters for intervention in the dog: causes for dystocia and treatment recommendations. *Reprod Domest Anim* 2009;44:141-147.
4. Darvelid AW, Linde-Forsberg C: Dystocia in the bitch: a retrospective study of 182 cases. *J Small Anim Pract* 1994;35:402-407.
5. Traas AM: Surgical management of canine and feline dystocia. *Theriogenology* 2008;70:337-342.
6. LeBlanc MM: Common peripartum problems in the mare. *J Equine Vet Sci* 2008;28:709-715.
7. Frazer GS: Post partum complications in the mare. Part 2: Fetal membrane retention and conditions of the gastrointestinal tract, bladder and vagina. *Equine Vet Educ* 2003;15:91-100.
8. Fresno L, Marco A, Calvo MA, et al: Fibrino-purulent necrotizing metritis as a post-surgical complication after a prolonged delivery in a bitch: a case report. *Int J Vet Med: Res Reports* 2014;1-8.
9. Humm KR, Adamantos SE, Benigni L, et al: Uterine rupture and septic peritonitis following dystocia and assisted delivery in a Great Dane bitch. *J Am Anim Hosp Assoc* 2010;46:353-357.
10. Sontas BH, Apaydin SO, Toydemir TS, et al: Perineal hernia because of retroflexion of the urinary bladder in a Rottweiler bitch during pregnancy. *J Small Anim Pract* 2008;49:421-425.

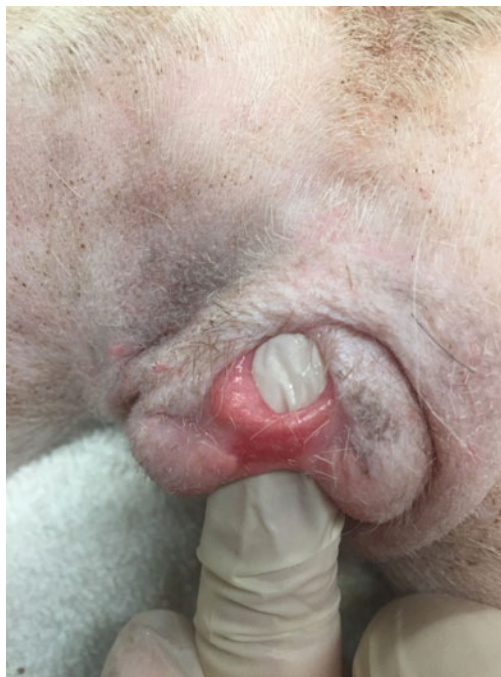

Figure 1. Perineal laceration five weeks after whelping. The dorsal aspect of the vulvar lips have healed together, while the remainder of the laceration is complete.

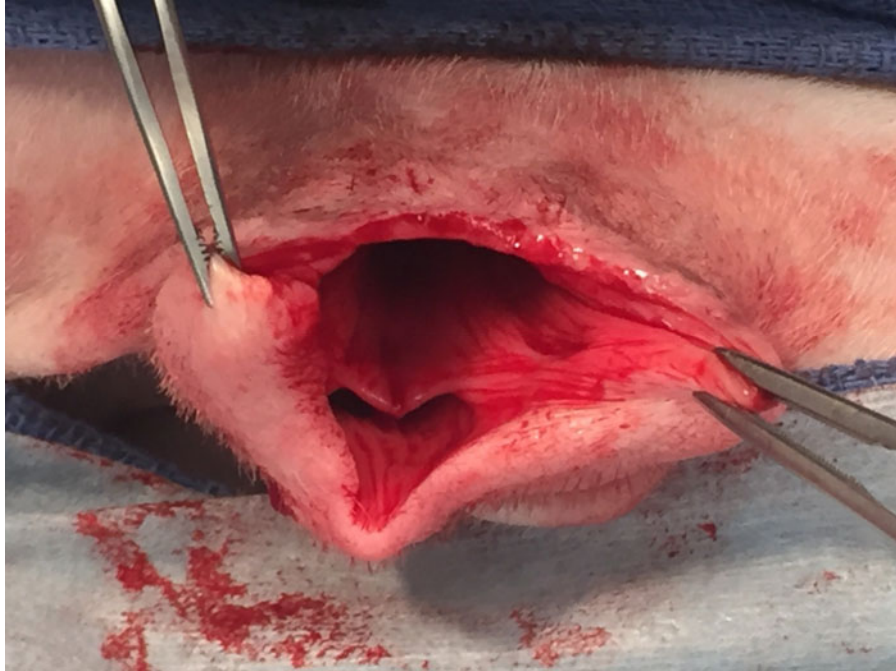


Figure 2. Intra-operative view of the laceration after freshening the edges of the wound.

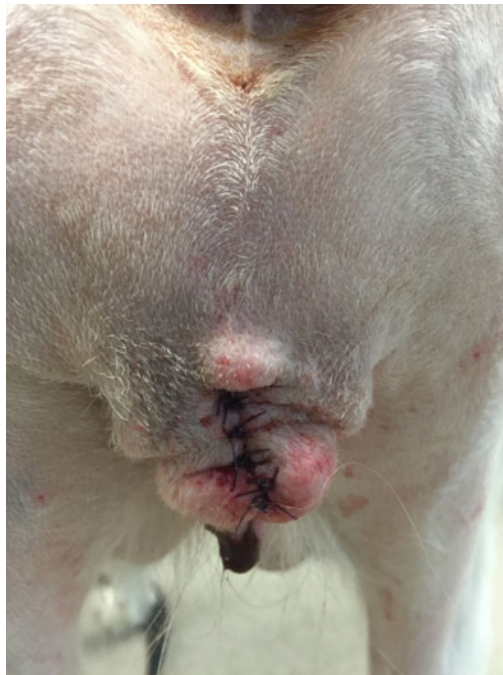

Figure 3. View of the laceration following repair.

(Editor's Note: The photographs in this manuscript are available in color in the online edition of *Clinical Theriogenology*.)